

Analysis of Traditional Scalp Acupuncture Point Locations as Local Cortical Region and Functional Network Node Targets in Non-Invasive Brain Network Neuromodulation

Section 1 - The Lateral Frontal Lobe

Douglas S. Wingate

Abstract

Background/Objective: Non-invasive neuromodulation techniques have increasingly been utilized and investigated as potential treatment approaches for neurological and psychiatric disorders. Increasing evidence supports the possibility of non-invasive neuromodulation affecting larger scale brain networks rather than just local stimulation targets. In this article, this concept and implications thereof are explored within the context of traditional acupuncture points located on the scalp and their cortical region correlates.

Method: This article addresses the conceptual framework of traditional acupuncture point locations on the scalp as potential local cortical region and/or neural network nodes of non-invasive neuromodulation modalities and may expand existing understanding of the influence of scalp acupuncture points based on these network connections. Studies that support this hypothesis are provided followed by an exploration of functionally and structurally connected brain parcellations elucidated by connectomic mapping and correlations with traditional acupuncture points. In this installment cortical regions of the lateral frontal lobe are explored.

Main Results/Conclusion: Studies stimulating brain regions by various non-invasive methods including manual and laser scalp acupuncture, repetitive Transcranial Magnetic Stimulation (rTMS), and transcranial Direct Current Stimulation (tDCS) offer evidence of underlying neuromodulatory mechanisms and clinical therapeutic effect in cases of various neuropathologies. These effects have evidence to support that in addition to local cortical region responses; structural and functional brain network modulatory influence including influence upon deeper brain structures, have been demonstrated. In light of this evidence, it is proposed that applying a network perspective to non-invasive transcranial stimulation may lend a broader understanding of therapeutic potential in using these techniques.

Keywords: scalp acupuncture, connectome, neuromodulation, brain networks, brain hubs, dorsolateral prefrontal cortex

Introduction and Theoretical Basis

Scalp Acupuncture

Acupuncture has been performed on the scalp for centuries¹, with numerous traditional points lying along varying “meridians” that are said to traverse particular portions of the scalp as well as the rest of the body with therapeutic indications specifically attributed to each point.² More recently a number of scalp systems or “microsystems” have been developed and utilized in clinical practice³ including the “Zhu’s Scalp Acupuncture” (ZSA) developed by Dr. Ming Qing Zhu⁴, Yamamoto New Scalp Acupuncture (YNSA) developed by Dr. Toshikatsu Yamamoto in the 1960’s⁵, and the “Jiao” scalp system developed by Dr. Jiao, Shunfa that has been in use since 1971.⁶

Dr. Jiao’s scalp acupuncture system established a modern technique combining traditional needling methods with western medical knowledge of representative areas of the cerebral cortex, including anatomy, physiology, pathology, and neurology.⁷ It was derived from biomedical understanding of the nervous system and acts to stimulate specific areas such as the motor cortex, somatosensory cortex area, and praxis area. The scalp areas corresponding to the functional locations of the cerebral cortex are taken as the stimulating areas in scalp acupuncture for the treatment of diseases.⁸ Scalp acupuncture techniques have been demonstrated to have a number of neuromodulatory effects including increasing cerebral blood flow to local brain regions,⁹ exerting neuroprotective properties through upregulation of gene and protein expression of nerve growth factor (NGF)¹⁰, and enhancing functional connectivity between neural networks.¹¹

Scalp acupuncture has been studied in a variety of conditions including pain,¹² stroke,^{13,14} post-stroke hemiplegia,¹⁵ neurocognitive deficits and dementia,¹⁶ and neuropsychological disorders¹⁷ including anxiety¹⁸ and depression.¹⁹ Studies have also demonstrated clinical efficacy of laser acupuncture in eliciting a cortical response.^{20, 21}

Other Non-invasive neuromodulatory techniques

In neurorehabilitation, non-invasive neuromodulation techniques, such as repetitive Transcranial Magnetic Stimulation (rTMS) and transcranial Direct Current Stimulation (tDCS) are assumed to induce neuroplastic changes through the application of magnetic or electrical stimuli, respectively, directly to a brain area.²² These interventions are considered to influence neurophysiological mechanisms responsible for neuroplasticity by modulating glutamatergic pyramidal neuron excitability in the underlying cortex - potentiating glutamatergic receptors and decreasing GABA neurotransmission.²³ In rTMS, brief high-current pulses are produced in a coil of wire, called the magnetic coil, modulating cortical excitability using either inhibitory, low-frequency (≤ 1 Hz) or facilitatory high-frequency (≥ 5 Hz) stimulation.²⁴ TDCS influences brain excitability by using a low level of continuous electrical current. For tDCS, two (or more) electrodes are placed on the scalp with the current going from the anode to the cathode. As opposed to rTMS, the electrical currents delivered by tDCS are not strong enough to fire an action potential.²⁵ During these procedures several factors can influence excitatory/inhibitory changes of brain stimulation²⁶ including the state of the brain during stimulation (at rest or paired with a task)²⁷, any intake of substances such as nicotine²⁸ and even the time of the day.²⁹ This sliding of the modification threshold for increased or decreased excitation, depending on the previous history of neural activity is referred as “metaplasticity” or “homeostatic plasticity”^{30, 31}

A study of non-invasive electrical stimulation of the primary motor cortex concluded that while local brain region activation was present, their findings suggested that stimulation “is not influencing the target area in isolation, but rather a brain network”.³² It has additionally been demonstrated that non-invasive neuromodulatory techniques applied to the surface of the scalp can influence deeper brain structures not directly below the stimulation point via network connections in a similar manner to those along the brain’s external surface.³³

Taking this into account, it has been proposed that “the brain is a complex network and, therefore, studying and treating brain disorders using non-invasive neuromodulation techniques should be approached as a network phenomenon.”³⁴ and that “knowledge of structural connectivity pathways can be used to target a network of brain areas rather than a single area.”³⁵

Connectomics

The connectome is a map of all neural connections in the brain. Connectomics is the study and mapping of these connections.³⁶ In 2009, the Human Connectome Project³⁷ commenced a five-year effort to digitally map the structural and functional neural connections in the human brain. The \$38.5M project began with a Blueprint Grand Challenge grant from the National Institute of Health and formed consortiums across top neuroscience institutions in the world including Washington University, Oxford, the University of Minnesota, Harvard, and UCLA.³⁸ The result was a new brain map, the HCP Parcellation, or Atlas, that defined discrete brain areas based on their *functional* roles and how they were both functionally and structurally connected. This included 83 areas from previous studies and 97 that were previously unknown, totaling 180 in each hemisphere.³⁹ This series of articles will map out all 180 parcellations relative to traditional acupuncture points along with their structural and functional connections using “A Connectomic Atlas of the Human Cerebrum” by Baker et al.⁴⁰ as a primary source.

Both structural and functional connections are important to take into account as analyzing structural networks may help understand the fundamental architecture of interregional connections, functional networks directly elucidate how this architecture supports neurophysiological dynamics and while functional properties are expressed locally, they are the result of the action of the entire network as an integrated system.⁴¹ Structural connectivity places constraints on which functional interactions occur within the network.⁴¹ Additionally, there has been evidence presented of significant overlap between resting state networks and certain connectome harmonic patterns suggesting connectome harmonics provide a link dynamics of oscillatory cortical networks to human connectome anatomy.⁴²

Parcellations may be considered nodes within larger brain network dynamics. Some brain regions may be thought of as “hubs” with high degrees of structural or functional connections, or high “centrality”. The centrality of a node measures how many of the shortest paths between all other node pairs in the network pass through it. A node with high centrality is thus crucial to efficient communication within a network.⁴³

As connectomics has developed over time its implications in clinical symptomatology and neuropathologies have begun to be studied.⁴⁴ Within the context of brain network dynamics, lesions in different locations that cause the same symptom can be linked to common networks in ways not previously possible, termed “lesion network mapping”; and connectome localizations may expose new treatment targets for patients with complex neuropathologies.⁴⁴ Neurologic symptoms can also result from physiological changes in anatomically intact brain regions that are distant from, but connected to the lesion -a phenomenon termed diaschisis.⁴⁵ This approach is an advance over traditional lesion analysis, because the same symptom is often caused by lesions in different locations as a result of the aforementioned connectivity, disconnection, and diaschisis.⁴⁶ Lesions that cause the greatest number of symptoms occur at the intersection of large white-matter pathways and at hubs that are functionally connected to large numbers of other brain regions.⁴⁷

Part 1: The Lateral Frontal Lobe / Dorsolateral Prefrontal Cortex

Much of the lateral frontal lobe regions explored in this article make up a region of the brain collectively known as the dorsolateral prefrontal cortex (DLPFC).⁴⁸ The DLPFC is associated with a number of higher cortical functions often referred to as “executive function” that play a role in the ability to select actions or thoughts in relation to internal goals.⁴⁹ More specifically, the DLPC has been demonstrated to play a primary role in what are referred to as “cold” executive functioning more closely related to logic and reasoning.⁵⁰ In cases of DLPFC dysfunction or lesions a number of symptoms related to these cold executive functioning may appear including: (1) problems with planning, organizing, and prioritizing; (2) a lack of attentional flexibility; (3) impaired concept formation; (4) poor working memory; and (5) an inability to monitor and adapt behavior consistent with changing social circumstances.⁵¹ Conscious components of cognition may also be impacted as anterior cingulate cortex (ACC) activation detects conflicts in processes accompanied by activation of the DLPFC that has been associated with top-down adjustments of response control.⁵²

In cases of concussion or traumatic brain injury, atypical brain activation patterns within the DLPFC have been found to occur.⁵³ Clusters of reduced fractional anisotropy (FA), an indicator of loss of white matter that may reflect damage myelin or axon membrane damage or reduced density or coherence, have been demonstrated within frontal white matter including in the DLPFC.⁵⁴ Indications of higher Mean Diffusivity (MD), which is inversely correlated with FA, has also been demonstrated compared to controls.⁵⁴ A study of male athletes post-concussion with atypical DLPFC

activation showed those who had resolution of their post-concussive symptoms demonstrated a significant increase in DLPFC functioning while those whose symptoms remained unchanged continued to demonstrate atypical DLPFC activation.⁵³ As such, the DLPFC and evaluation of its functioning plays an imperative role in traumatic brain injury evaluation and focal point of functional rehabilitation.⁵⁵

It has been suggested that the DLPFC can be considered a functional “flexible hub” of the brain.⁵⁶ Meaning, a brain region that rapidly updates its pattern of global functional connectivity according to task demands. These flexible hubs play an important role in switching from one state to another in order to attend to the necessary task demands with indications that modulating them can influence a whole brain network.⁵⁶

The prefrontal cortex (PFC), and specifically, the DLPFC has been the most frequently targeted brain region by non-invasive brain stimulation studies.⁵⁷ Transcranial direct current stimulation (tDCS) over the left DLPFC showed reconfiguration within intrinsic large-scale brain activity networks - the Default Mode Network (DMN) and the anticorrelated network⁵⁸ which has a strong negative activity correlation with the DMN and has an association with cognitive processing whereby focused attention on the external environment is required.⁵⁹ Anodal tDCS over the right DLPFC has demonstrated improvement on dual tasking score with a reduction in error rates.⁶⁰

Non-invasive neuromodulatory techniques over the DLPFC have been studied surrounding attention,⁶¹ depression, and cognition⁶² after traumatic brain injury; Parkinsonism in combination with fluoxetine,⁶³ depression/ affective processing,⁶⁴ transitory improvements in working memory⁶⁵ and attention,⁶⁶ PTSD,^{67,68} recognition memory in Alzheimer's disease,⁶⁹ schizophrenia including auditory hallucinations^{70,71} and addiction behaviors including alcohol⁷² and food.⁷³

Frontal Polar Region

Area 10pp

Location:

Anterior tip of the frontal pole. Located at the fusiform junction of the anterior-most aspects of the superior and middle frontal gyri.

Functions:

Area 10pp is involved in episodic and working memory tasks.

Brodmann area 10 more generally is activated in increasing complexity of working memory tasks.⁷⁴ This area also plays a role in abstract cognitive function.⁷⁷

Functional Connectivity:

Area 10pp lacks strong evidence of functional connectivity to other areas. There is borderline evidence of functional connectivity with:

Posterior dorsolateral frontal lobe: a10p, 8Av, 8C

Posterior cingulate gyrus: 31pd, 31pv

Inferior parietal lobe: PFm, PGI

Superior temporal sulcus: STSvp

White Matter Connections:

Structurally connected to the Inferior fronto-occipital fasciculus (IFOF) and contralateral hemisphere.

IFOF connections travel from 10pp through the extreme/external capsule and continue posteriorly to end at occipital lobe parcellations V1 and V2.

Contralateral connections course through the genu of the corpus callosum with the forceps minor to terminate at 10d and 10pp.

Local short association bundles: 10d

Traditional Acupoint Correlates:

Local Acupoint: N/A (near BL2)

Functionally Connected Acupoints:

GB6 (STSvp)

GB14 (a10p)

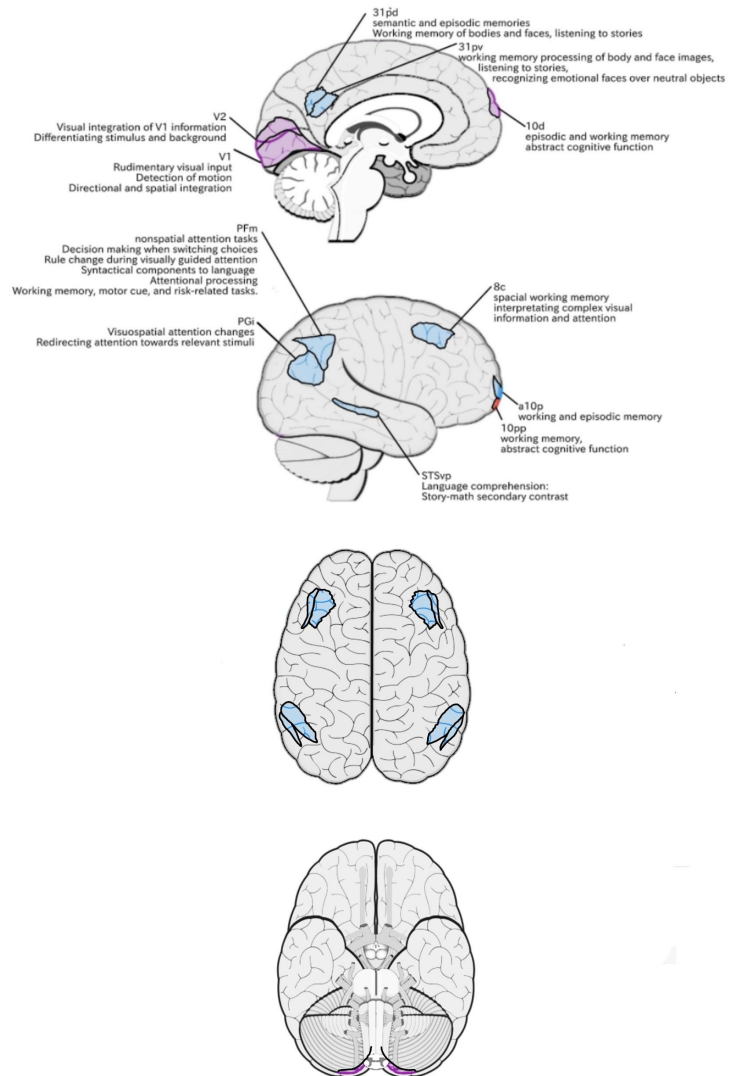
GB15 (8c)

GB18 (PFm)

Structurally Connected Acupoints:

GV18 (V1/V2)

GV24 (10d)



Area 10d (10 dorsal)

Location:

in the anterior SFG. It wraps into the interhemispheric fissure, lying on the medial bank.

Functions:

-Episodic and working memory tasks.

Brodmann area 10 more generally is activated in increasing complexity of working memory tasks.⁷⁴ This area also plays a role in abstract cognitive function.⁷⁵

Functional Connectivity:

Anterior frontal lobe: 10r, 10v, 9m, 9P, 8BL, 8AV

Anterior cingulate cortex: s32, d32, a24

Posterior cingulate cortex: POS1, 7M, 31a, 31pv, 31pd, v23ab

Middle temporal gyrus: STSva, TE1a

Inferior parietal lobe: PGs, PGI

Hippocampus

Many of these areas correspond to regions typically associated with the default mode network (DMN)

White Matter Connections:

Connections to the contralateral hemisphere travel through the genu of the corpus callosum with the forceps minor to end at 9a and 10d.

Local short association bundles: 10pp, a10p, 9a, 10r, 9m, and p32.

Traditional Acupoint Correlates:

Local Acupoint: GV24

Functionally Connected Acupoints:

BL3 (8BL/9P)

BL5 (8AV)

GB6 (STSvp/ TE1a)

GB15 (8Av)

GB18 (PGs)

GV22 (8BL)

GV23 (9m/10d)

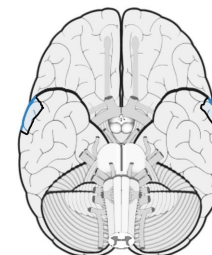
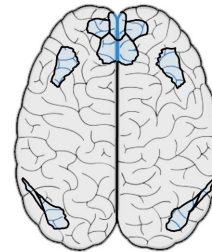
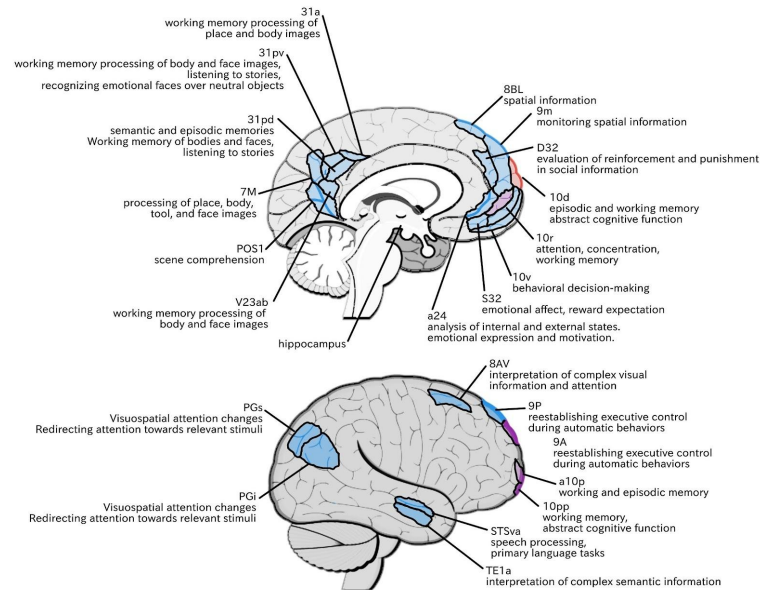
GV24 (9m)

Structurally Connected Acupoints:

GB14 (a10p)

GV23 (9a/10d)

GV24 (10d)



Area a10p (anterior 10 polar)

Location:

At the fusiform junction of the anterior most aspects of the superior and middle frontal gyri.

Function:

-Episodic and working memory tasks.

Brodmann area 10 more generally is activated in increasing complexity of working memory tasks.⁷⁴ This area also plays a role in abstract cognitive function.⁷⁵

Functional Connectivity:

Dorsolateral frontal lobe: p10p, a9-46v, 8BM, 8C
 Anterior cingulate region: d32
 Lateral parietal lobe: PFm
 Medial parietal lobe: POS2 and 7pm

White Matter Connections:

The IFOF and contralateral hemisphere.
 Contralateral connections travel through the genu of the corpus callosum with the forceps minor to end at 9a and p10p.
 IFOF connections travel from a10p through the external capsule, continuing posteriorly to end at V1, V2, V3, V6, and V6a.
 Local short association bundles: 10d, 10pp, p10p, a9-46v, and 9-46d.

Traditional Acupoint Correlates:

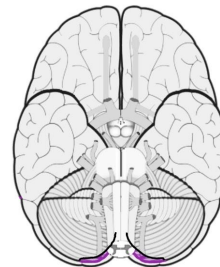
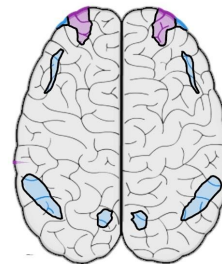
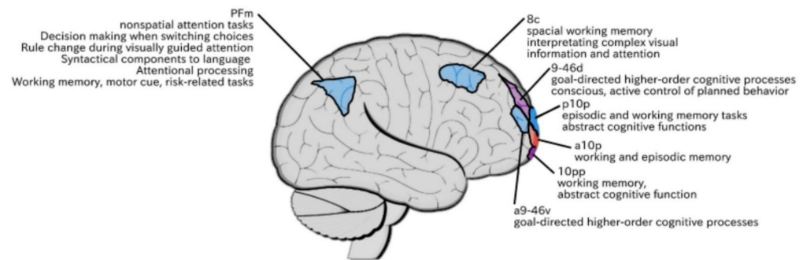
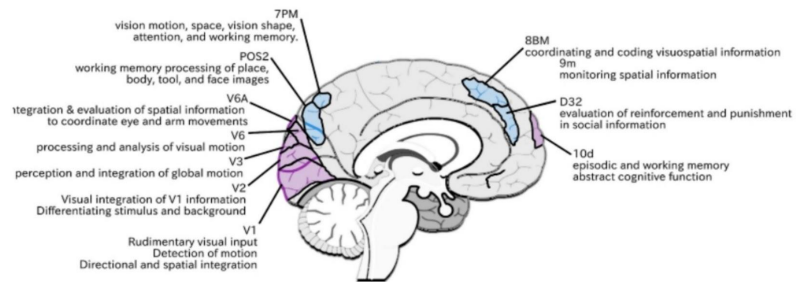
Local Acupoint: GB14

Functionally Connected Acupoints:

GB15 (8C)
 GB18 (PFm)
 GV19 (7PM)

Structurally Connected Acupoints:

BL4 (9-46d)
 GV18 (V1/V2)
 GV19 (V6a)
 GV24 (10d)



Area p10p (posterior 10 polar)

Location:

on the lateral bank of the anterior aspect of the SFG, just posterior to a10p. Straddles the anterior most point of the superior frontal sulcus (SFS) that terminates here.

Function:

-Episodic and working memory tasks.

Brodmann area 10 more generally is activated in increasing complexity of working memory tasks.⁷⁴ This area also plays a role in abstract cognitive function.⁷⁵

Functional Connectivity:

Anterior frontal lobe: a10p, a9-46v

Anterior cingulate: d32

Posterior frontal lobe: i6-8

Posterior cingulate region: 31a, 31pv, d23ab, POS2,

retrosplenial cortex (RSC), 7pm

Inferior parietal lobule: PFm

White Matter Connections:

Structurally connected with the IFOF and contralateral hemisphere.

Contralateral connections travel through the genu of the corpus callosum with forceps minor to end at 9m.

IFOF connections travel from p10p through the external capsule and continue posteriorly to end at V1 and V2.

Local short association bundles: 9-46d, 10d, a10p, a9-46v, and p9-46v

Traditional Acupoint Correlates:

Local Acupoint: GB14

Functionally Connected Acupoints:

BL5 (i6-8)

GB14 (a10p)

GB18 (PFm)

GV19 (7PM)

Structurally Connected Acupoints:

BL4 (9-46d)

GB13 (p9-46v)

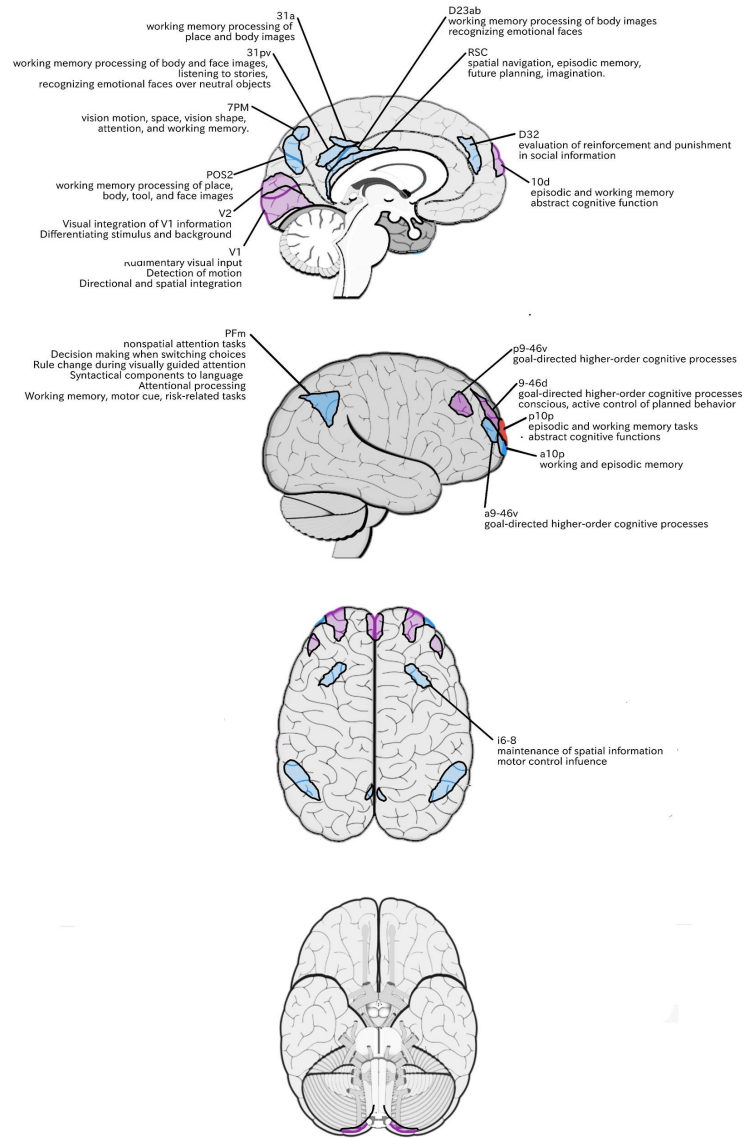
GB14 (a10p)

GB15 (p9-46v)

GV18 (V1/V2)

GV23 (9m)

GV24 (10d)



Area a47r (anterior 47 rostral)

Location:

A j-shaped area located at the anterior inferior portion of the pars orbitalis of the IFG.

Function:

-Controlled semantic retrieval

Functional Connectivity:

Dorsolateral frontal lobe: p47r, 8C, 8AV, 8BL, 8BM, i6-8, a9-46v, p9-46v

IFG regions: IFSa, IFSp, 47l, 45

Inferior parietal lobule: IP1, IP2, PGi, PGs, PFM

Lateral temporal lobe: TE1m, TE1p, TE2a, STSv

Posterior cingulate region: d23ab

White Matter Connections:

Structurally connected to the IFOF.

IFOF connections travel from a47r through the extreme/external capsule and continue posteriorly to end at V1, V2, V3, V3a, V6, V6a, 7AM, and 7PL.

Local short association bundles: 47m, 11L

Traditional Acupoint Correlates:

Local Acupoint: GB14

Functionally Connected Acupoints:

BL5 (i6-8/8AV)

GB6 (STSv)

GB7 (TE1m, TE2a)

GB8 (TE1p)

GB15 (8AV, 8C, p9-46v)

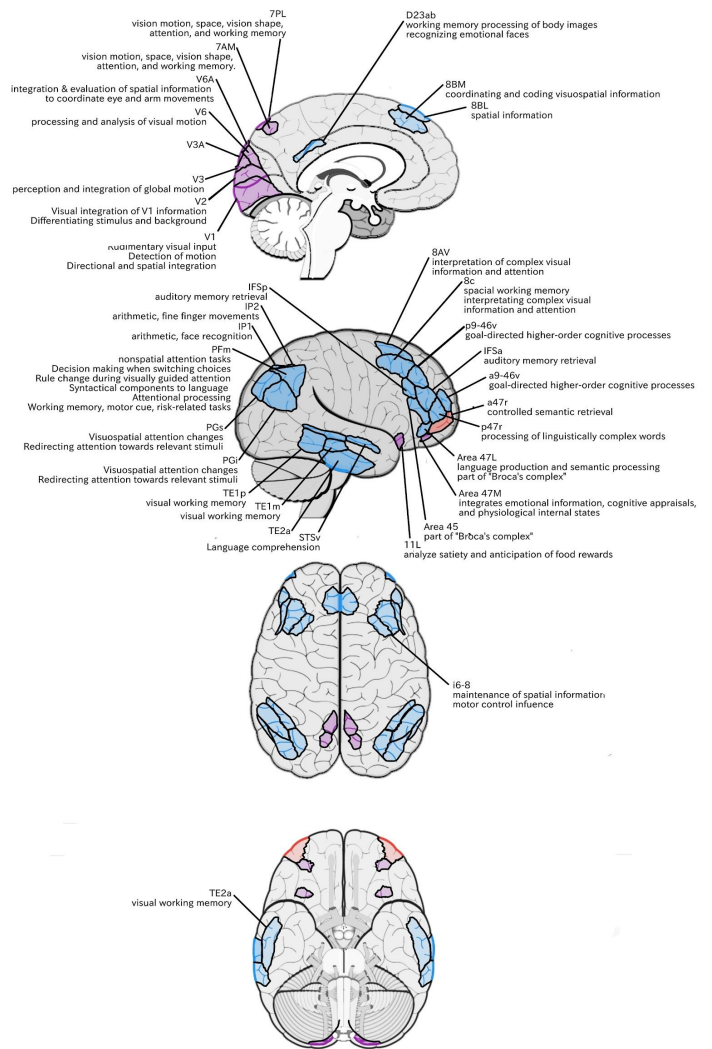
GB18 (PFm/PGs/IP1)

GV22 (8BL)

Structurally Connected Acupoints:

GV18 (V1/V2)

GV19 (V6a)



Area p47r (posterior 47 rostral)

Location:

The anterior end of the IFS in the anterosuperior most part of the IFG.

Functions:

Brodmann area 47: activated while processing linguistically complex words.⁷⁶

In the recognition of spoken language, Brodmann area 47 increases in activity as the cohort of spoken words increases in size.⁷⁷

Functional Connectivity:

Dorsolateral frontal lobe: a47r, a9-46v, p9-46v, 8BM, 8C, i6-8

Inferior frontal lobe: IFSa, IFSp, IFJp, 6r

Insula: anterior ventral insula (AVI)

Temporal lobe: areas TE1p, PHT

Inferior parietal lobe: PFm

Intraparietal area: IP2, IP1, LIPd

White Matter Connections:

Structurally connected with surrounding parcellations. The white matter tracts are highly inconsistent. Some individuals seem to have connections with the IFOF.

Local short association bundle connections: a47r, p10p, 45, IFSa, s6-8, 9-47d, and 9a.

Traditional Acupoint Correlates:

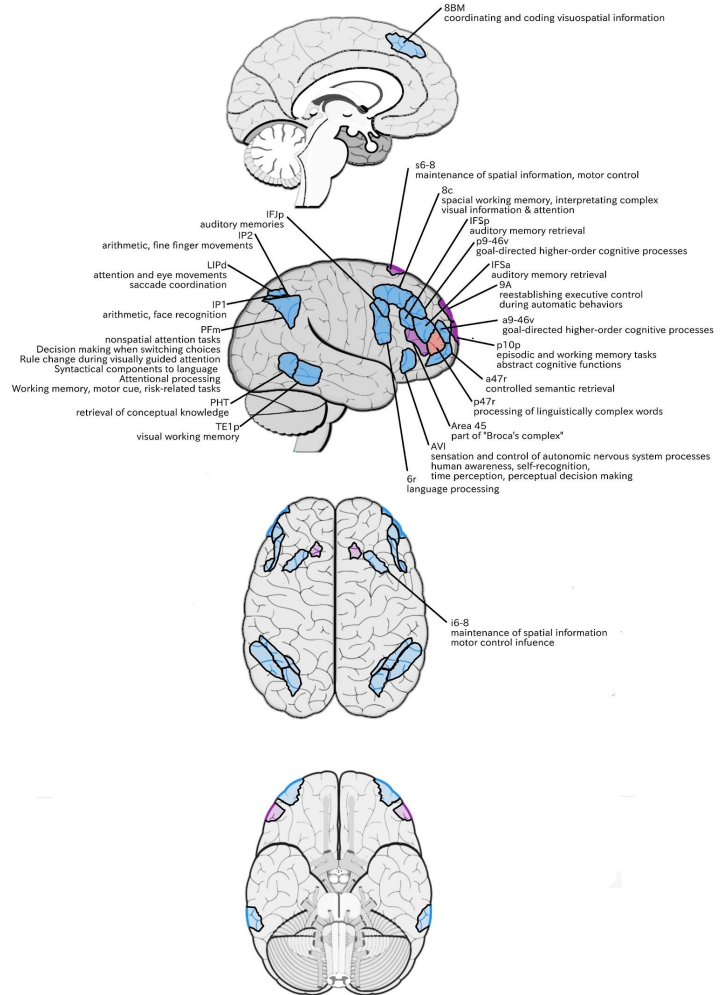
Local Acupoint: N/A (posterior to GB13)

Functionally Connected Acupoints:

- BL5 (i6-8)
- GB8 (TE1p/PHT)
- GB9 (PHT)
- GB12 (6r)
- GB13 (p9-46v)
- GB14 (a47r)
- GB15 (8C/p9-46v)
- GB18 (PFm/IP1),
- ST8 (6r/IFJp)

Structurally Connected Acupoints:

- GB14 (a47r/p10p)



Superior Frontal Gyrus (SFG) Regions

Area 9a (9 anterior)

Location:

Anterior portion of the superior surface of the SFG.

Functions:

Brodmann area 9: maintenance of behaviorally relevant working memory.⁷⁸

Area 9 along with Brodmann areas 46 and 8 play a role in reestablishing executive control during automatic behaviors.⁷⁹

Functional Connectivity:

Dorsolateral frontal lobe: 9p, 9m, 8BL, 8AV

Medial frontal lobe: SFL, d32

Inferior frontal lobe: 44, 45, 47l, 47s

Temporal lobe: TGd, TE1a, STSva, STSvp

Inferior parietal lobe: PGI and PFm

Medial parietal lobe: 7m, 31pd, 31pv, 23d

White Matter Connections:

Structurally connected to the IFOF and contralateral hemisphere. Some individuals also have medial thalamic connections but this is inconsistent.

Contralateral connections travel through the genu of the corpus callosum with the forceps minor to end at 9a, 9p, p10p, 10d, and 9m.

IFOF connections travel from 9a through the extreme/external capsule and continue posteriorly through the temporal lobe to end at V1, V2, and V3.

Local short association bundles: 9p.

Traditional Acupoint Correlates:

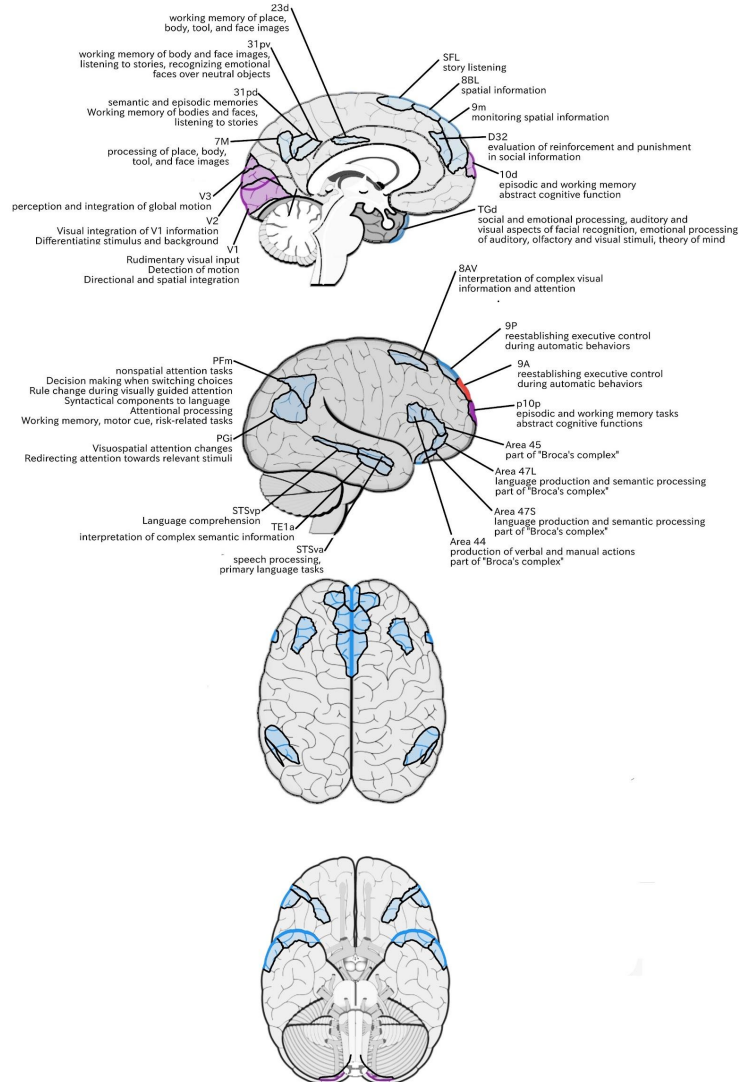
Local Acupoint: BL2

Functionally Connected Acupoints:

BL3 (8BL/9P)	GB18 (PFm)
BL5 (8AV)	GV21 (SFL)
GB6 (STSva/STSvp/TE1a)	GV22 (8BL)
GB15 (8AV)	GV23 (9m)

Structurally Connected Acupoints:

GB14 (p10p)	GV23 (9m/10d)
GV18 (V1/V2)	GV24 (10d)



Area 9p (9 posterior)

Location:

Anterior portion of the superior surface of the SFG.

Functions:

Brodmann area 9: maintenance of behaviorally relevant working memory.⁷⁸

Area 9 along with Brodmann areas 46 and 8 plays a role in reestablishing executive control during automatic behaviors.⁷⁹

Functional Connectivity:

Dorsolateral frontal lobe: 9a, 9m, 8BL, 8AD, 8AV

Medial frontal lobe: SFL, 10r, a24, d32

Inferior frontal lobe: 45, 47l, 47s

Temporal lobe: TGd, TE1a, STSva, STSvp

Inferior parietal lobe: PGI, PGs

Medial parietal lobe: 7m, 31pd, 31pv, 23d, d23ab, v23ab

White Matter Connections:

Structurally connected to the IFOF, contralateral hemisphere and the medial thalamus. Contralateral connections course through the genu of the corpus callosum with the forceps minor to end at 8BL, 9a, 9p, and 9m.

Connections with the thalamus travel through the anterior limb of the internal capsule.

IFOF connections travel from 9p through the external capsule and continue posteriorly through the temporal lobe to end at V1, V2, V3, V3A, and V6.

Local short association bundles: 9a, 8BL, and 9-46d

Traditional Acupoint Correlates:

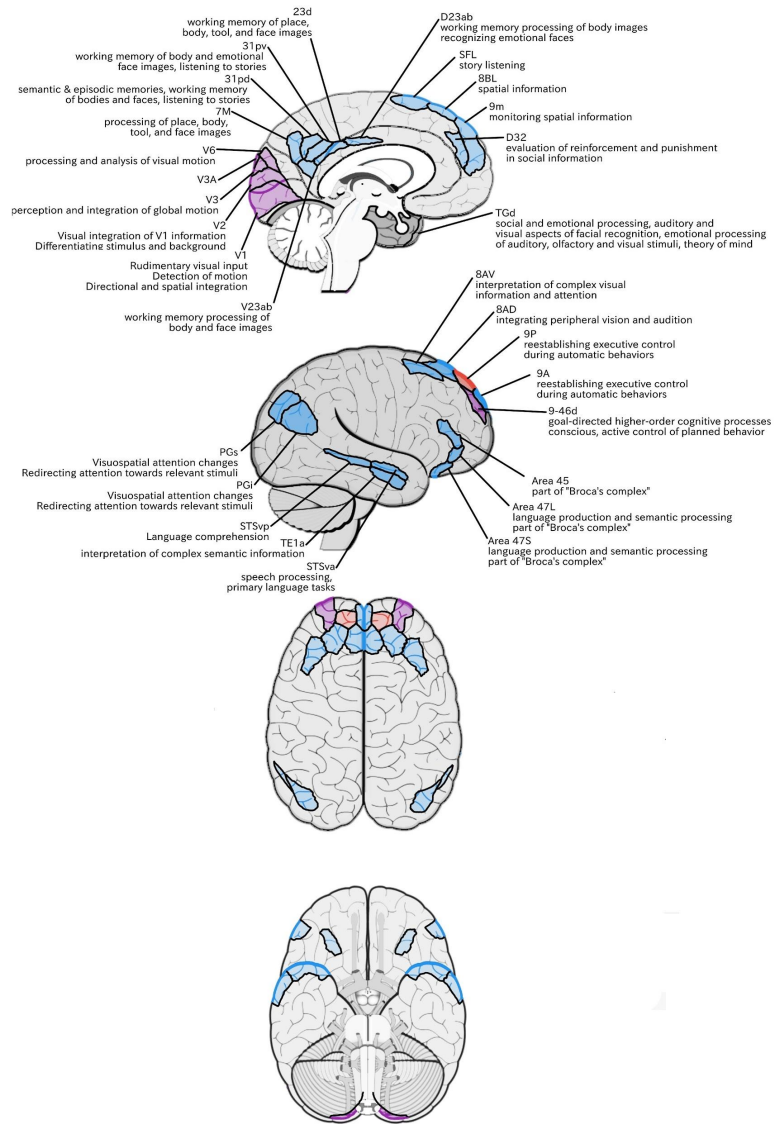
Local Acupoint: BL3

Functionally Connected Acupoints:

- BL3 (8AD/8BL)
- BL4 (8AD)
- BL5 (8AD/8AV)
- GB6 (STSva/STSvp/TE1a)
- GB15 (8AD/8AV)
- GB18 (PGs)
- GV22 (8BL)
- GV23 (9m)

Structurally Connected Acupoints:

- BL3 (8BL)
- BL4 (9-46d)
- GV18 (V1/V2)
- GV23 (9m)



Area 8BL (8B lateral)

Location:

Posterior half of the superior surface of the SFG.

Function:

Area 8B in macaques: coordination of eye and ear movements in relation to space and topographical representation of that space.⁸⁰

Areas 8 and 6 also play a role in the maintenance of spatial information.⁸¹

Functional Connectivity:

Dorsolateral frontal lobe: 9a, 9m, 8BM, 8C, 8AV

Medial frontal lobe: SFL, 10d, 10v, d32

Inferior frontal lobe: a47r, 44, 45, 47l, 47s

Temporal lobe: TGd, TE1a, TE1m, TE2a, STSdp, STSva, STSvp

Inferior parietal lobe: PGi, PGs

Medial parietal lobe: 7m, 31pd, 31pv, 23d, d23ab, v23ab

White Matter Connections:

Structurally connected to the IFOF, contralateral hemisphere, medial thalamus and FAT.

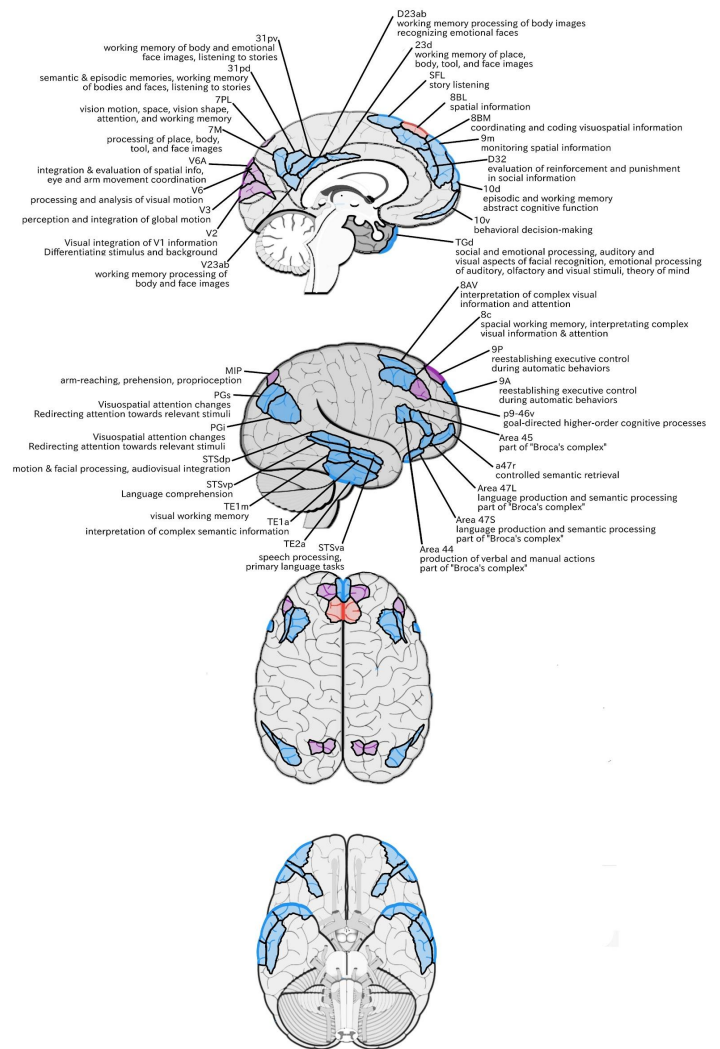
Contralateral connections course through corpus callosum with the forceps minor to end at 8BM and 9m.

Medial thalamic connections travel through the anterior limb of the internal capsule. IFOF connections pass through the extreme/external capsule and continue posteriorly to end at V2, V3, 7PL, MIP, V6, and V6A.

From 8BL, the FAT projects to the IFG to terminate at 44.

From this tract there are also connections with p9-46v.

Local short association bundles: SFL, 8BM, 9a, and 9p



Traditional Acupoint Correlates:

Local Acupoint: GV22

Functionally Connected Acupoints:

BL4 (8AD)

BL5 (8AD)

GB6 (STSdp/STSva/STSvp/TE1a)

GB7 (TE1m/TE2a)

GB15 (8AD/8C)

GB18 (PGs)

TW22 (TE2a)

GV23 (9m)

Structurally Connected Acupoints:

BL3 (9P)

GB13 (p9-46v)

GB15 (p9-46v)

GV21 (SFL)

GV18 (V2)

GV23 (9m)

Area 8AD (8A dorsal)

Location:

Posterior lateral part of the SFG on the banks of SFS.

Functions:

-Integrating information related to peripheral vision and audition in the context of spatial cognition.⁸²

The SFS is also involved in auditory spatial processing.⁸³ The posterior SFS anterior to the FEF is specialized for handling spatial working memory.⁸⁴

Functional Connectivity:

Dorsolateral frontal lobe: 9p, s6-8, i6-8, 10d, p10p, 8C, 8AV

Medial frontal lobe: 10r, a24, p32, s32, d32

Orbitofrontal region: 47m

Temporal lobe: STSva, PHA1, PHA2, PreS, EC, TE1p, TE1m, TE1a

Hippocampus

Inferior parietal lobe: PFm, PGI, PGCs

Medial parietal lobe: 7m, 7pm, 31pd, 31pv, 31a, RSC, PCV, 23d, d23ab, v23ab

White Matter Connections:

Structurally connected to local parcellations.

White matter tracts are highly inconsistent, in some individuals connecting with the FAT and contralateral hemisphere.

Local short association bundles: 9a, 9p, s6-8, 8AV, 6a, p10p.

White matter connections in the right hemisphere have more consistent connections with the contralateral hemisphere.

Traditional Acupoint Correlates:

Local Acupoint: BL3, BL4, BL5

Functionally Connected Acupoints:

BL3 (9P)

BL5 (8AV/i6-8)

GB6 (STSva/TE1a)

GB7 (TE1m)

GB8 (TE1p)

GB14 (p10p)

GB15 (8AV/8C)

GB18 (PFm, PGCs)

GV19 (7PM)

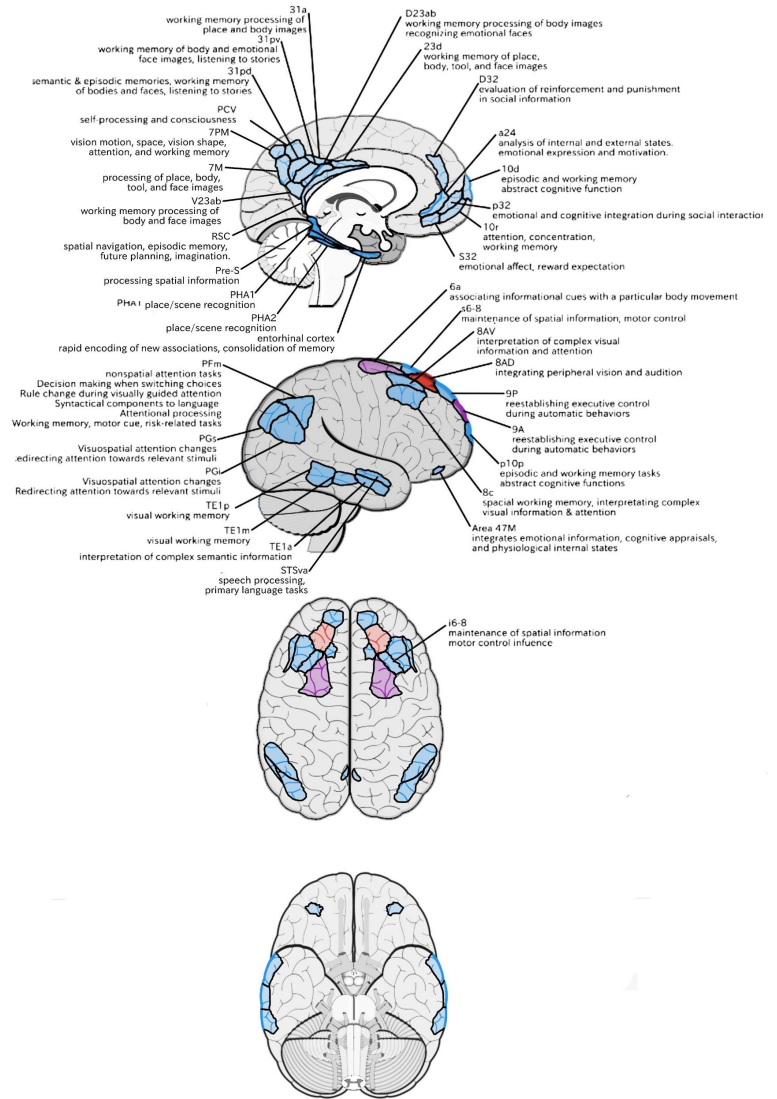
GV24 (10d)

Structurally Connected Acupoints:

BL5 (8AV)

BL6 (6a)

GB14 (p10p)



MFG and SFS Regions

Area 9-46d (9-46 dorsal)

Location:

Runs across the SFS at a slightly oblique, anterior-to-posterior angle in the depths of the anterior SFS.

Functions:

Area 9-46d, like area 46, plays a role in goal-directed higher-order cognitive processes.⁸⁵

The mid-DLPFC, which includes areas 9-46 and 46, is also involved in the conscious, active control of planned behavior.⁸⁶

Functional Connectivity:

Dorsolateral frontal lobe: 46, a9-46v, p9-46v, FEF
 Medial frontal lobe: SCEF, a32prime, p32prime, p24, a24pr
 Premotor regions: 6a, 6r, PEF
 Insula-opercular region: FOP1, FOP3, FOP4, FOP5, PSL, PFop, PFcm, AVI, 43 Pol1, MI
 Temporal lobe: PHT
 Parietal lobe: PF, 7AL, 7PL, LIPd
 Medial parietal lobe: POS2, PCV, 7am, 7pm, 23c, DVT
 Occipital lobe: V1, V2, V3, V4, V6

White Matter Connections:

Structurally connected to local parcellations and the contralateral hemisphere.
 Some individuals have connections with the IFOF, though this is inconsistent.
 Contralateral connections travel through the corpus callosum to end at 9m and 9p.
 Abundant local short association bundles: 8BL, 9p, 9-47d, 46, a9-46v, 8Ad, p47r, and a10p.

Traditional Acupoint Correlates:

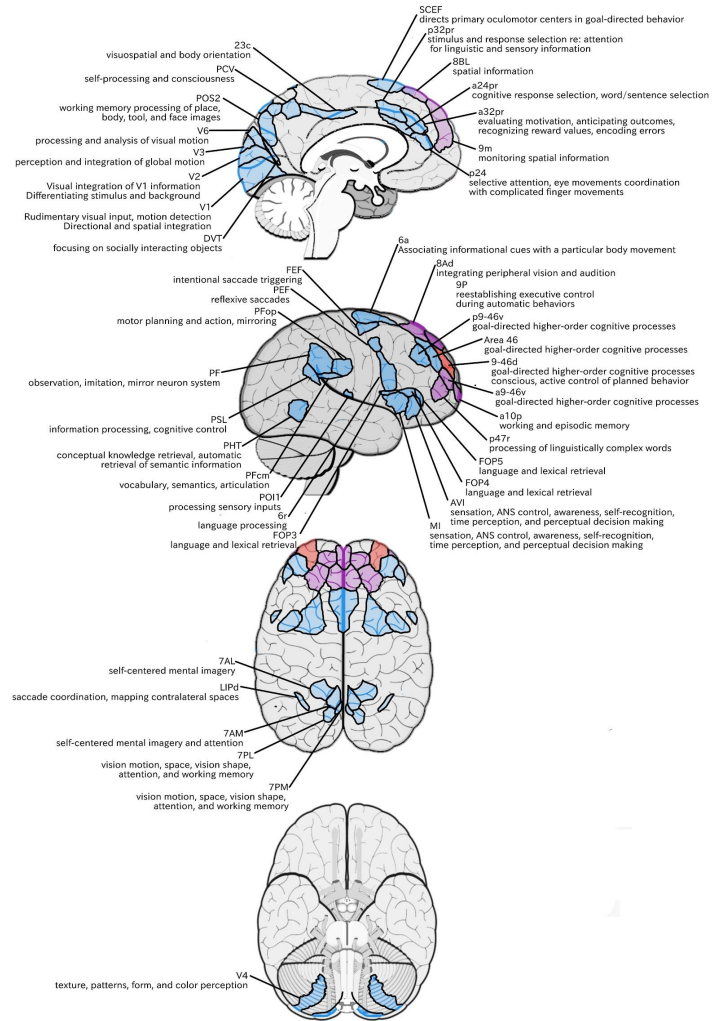
Local Acupoint: BL4

Functionally Connected Acupoints:

BL4 (Area 46)	GB8 (PHT)	GB16 (FEF)
BL5 (8Ad)	GB9 (PHT)	ST8 (6r)
BL6 (6a)	GB13 (p9-46v)	GV19 (7PM)
BL7 (7AL)	GB14 (a10p)	GV21 (SCEF)
GB4 (6r)	GB15 (p9-46v)	

Structurally Connected Acupoints:

BL3 (9P/8Ad)
 BL4 (8AD/Area 46)
 GV22 (8BL)
 GV23 (9m)



Area 46

Location:

Parallels area 9-46d along its slightly oblique course, beginning in the depths of the SFS posteriorly and its anterior extent spills onto the MFG.

Functions:

-Goal-directed higher-order cognitive processes.⁸⁵

The mid-DLPFC, which includes areas 9-46 and 46, is also involved in the conscious, active control of planned behavior.⁸⁶

Functional Connectivity:

Dorsolateral frontal lobe: a9-46v, p9-46v, IFSa

Medial frontal lobe: SCEF, a32prime, p24prime, a24prime

Premotor regions: 6ma, 6a, 6r

Orbitofrontal region: 11L

Insula-opercular region: FOP1, FOP3, FOP4, FOP5, 52

PFop, PFcm, 43 Pol2, Pol1, MI

Temporal lobe: PHT

Parietal lobe: PF, Pft, PGp, AIP, MIP, 7AL, 7PL, LIPd, IP2, IP0

Medial parietal lobe: 23c, PCV, POS2, 7am, 7pm, DVT

Occipital lobe: V1, V2, V3, V4, V3a, V6

White Matter Connections:

Structurally connected to local parcellations and the contralateral hemisphere.

Contralateral connections travel through the corpus callosum to end at 9-46d and p9-47v.

Abundant local short association bundles: 9-46d, a9-46v, p9-46v, IFSp, and IFSa

Traditional Acupoint Correlates:

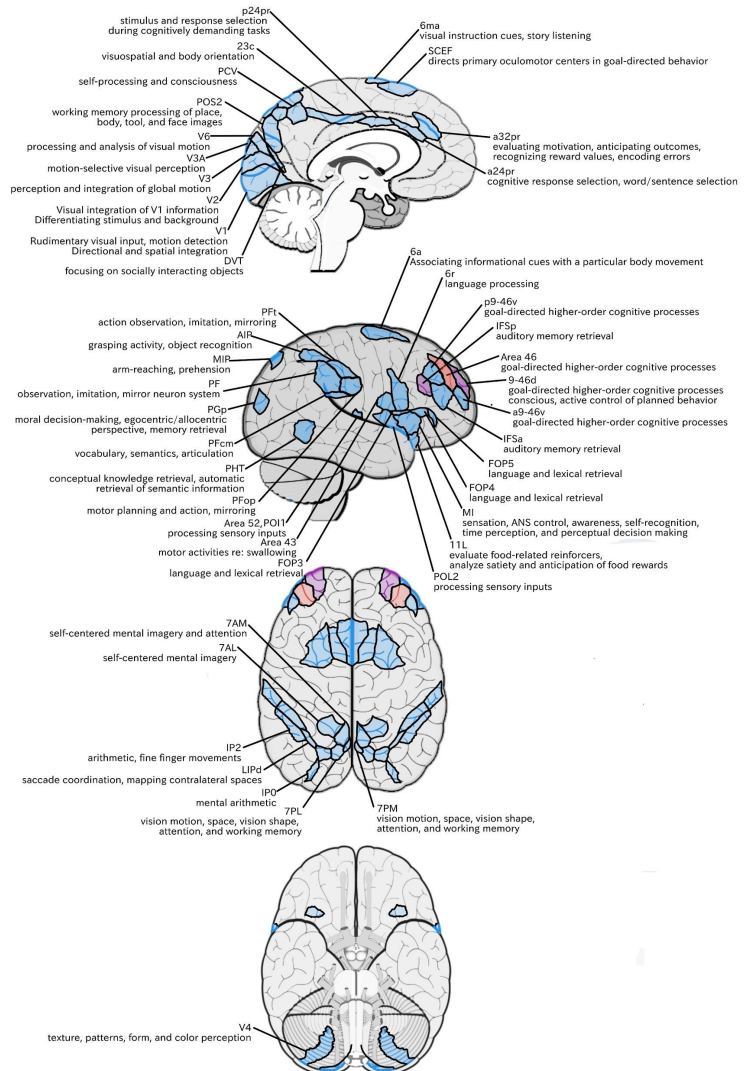
Local Acupoint: BL4

Functionally Connected Acupoints:

BL6 (6a)	GB8 (PHT)
BL7 (7AL)	GB9 (PHT)
BL8 (IP0)	GB13 (p9-46v)
GB4 (6r/Area 43)	GB15 (p9-46v)
GB5 (POL2)	GB18 (AIP)

Structurally Connected Acupoints:

BL4 (9-46d)
GB13 (p9-46v)
GB15 (p9-46v)



Area a9-46v (anterior 46 ventral)

Location:

At the anterior portion of the MFG.

Functions:

-Goal-directed higher-order cognitive processes.⁸⁵

The mid-DLPFC, which includes areas 9-46 and 46, is also involved in the conscious, active control of planned behavior.⁸⁶

Functional Connectivity:

Dorsolateral frontal lobe: 46, 9-46d, p9-46v, a10p,

p10p, 6ma, i6-8, a47r, p47r, 8C, IFSa

Medial frontal lobe: 8BM, a32prime

Orbitofrontal region: 11L

Temporal lobe: TE1p

Insula: AVI

Parietal lobe: LIPd, PF, IP1, IP2

Medial parietal lobe: 7pm, 31a, RSC

White Matter Connections:

Structurally connected to local parcellations. White matter tracts from this parcellation are highly variable.

Short association bundles: 8C, 9-46d, 46, IFSa, p47r

Traditional Acupoint Correlates:

Local Acupoint: N/A (posterior to GB13)

Functionally Connected Acupoints:

BL4 (Area 46/9-46d)

BL5 (i6-8)

BL8 (IP1)

GB7 (TE1p)

GB8 (TE1p)

GB13 (p9-46v)

GB14 (a10p/p10p),

GB15 (8C, p9-46d, Area 46)

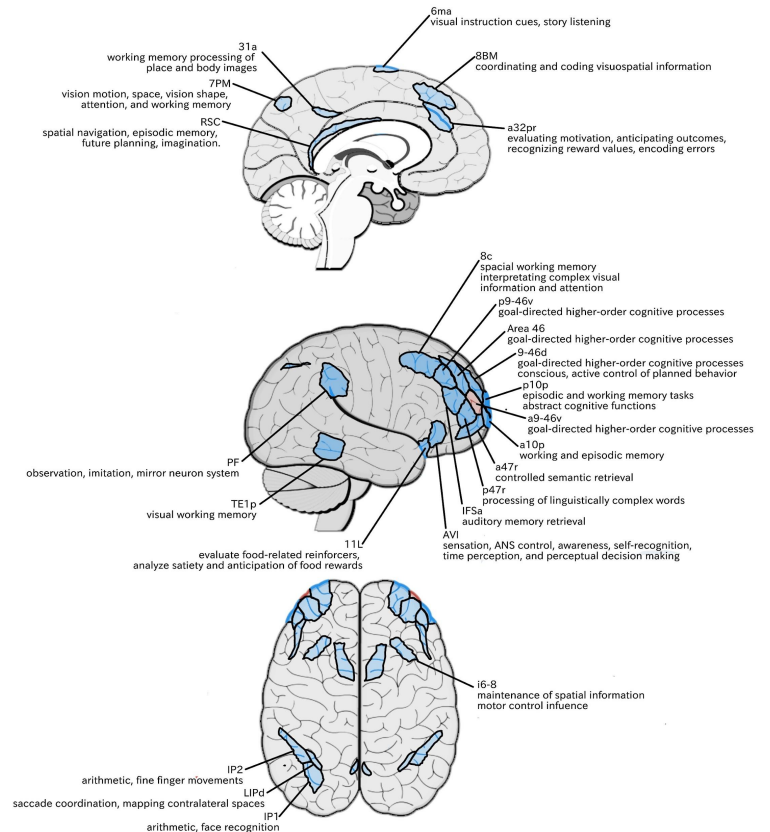
GB18 (IP1),

GV19 (7PM)

Structurally Connected Acupoints:

BL4 (Area 46/9-46d)

GB15 (8C, p9-46d, Area 46)



Area p9-46v (posterior 46 ventral)

Location:

A small triangular shaped region located in the MFG.

Functions:

-Goal-directed higher-order cognitive processes.⁸⁵

The mid-DLPFC, which includes areas 9-46 and 46, is also involved in the conscious, active control of planned behavior.⁸⁶

Functional Connectivity:

Dorsolateral frontal lobe: area 46, 9-46d, a9-46v a10p, p10p, 6ma, i6-8, a47r, p47r, 8C, IFJp, IFJa, IFSp, IFSa

Medial frontal lobe: 8BM, 33prime

Premotor area: 6a, 6r

Orbitofrontal region: 11L

Temporal lobe: areas TE1p, TE2p, PH, and PHT

Insula: area AVI

Parietal lobe: LIPd, AIP, MIP, PFm, 7PL, IP0, IP1, IP2

Medial parietal lobe: 7PM

Occipital lobe: area V1

White Matter Connections:

Structurally connected to the arcuate/SLF projecting posteriorly and wrapping around the sylvian fissure to the inferior temporal gyrus to end at TE2a.

Local short association bundles: area 46, a9-46v, IFJa, IFSa, IFSp, 8C, and 9-46d

Traditional Acupoint Correlates:

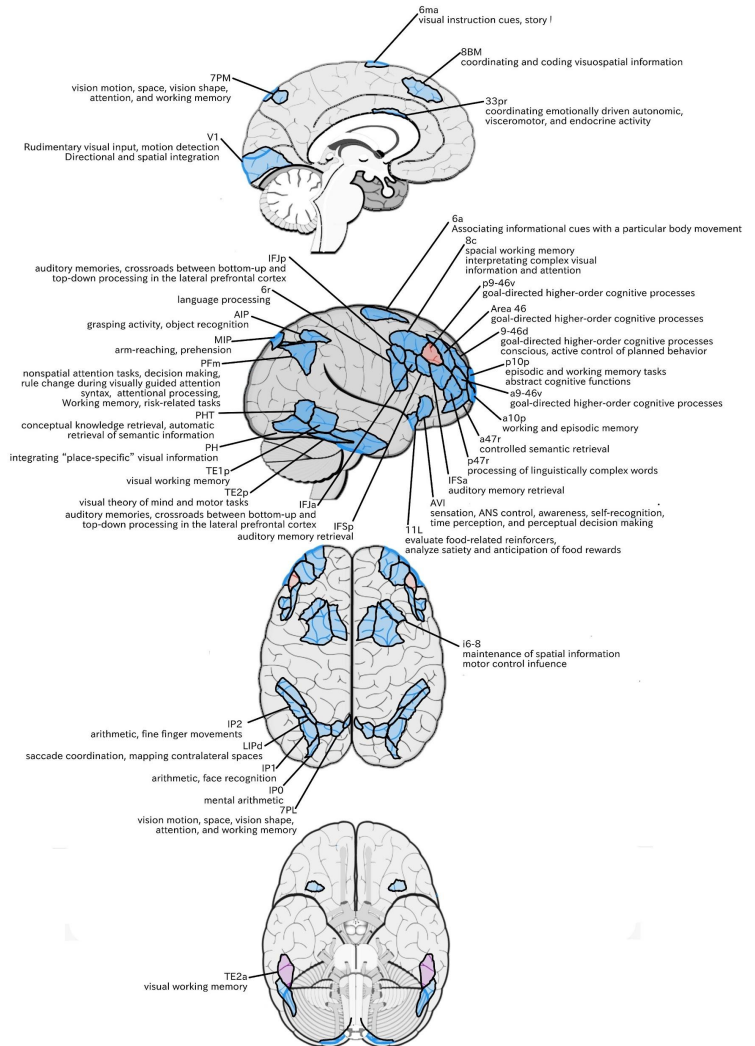
Local Acupoint: GB13, GB15

Functionally Connected Acupoints:

BL4 (Area 46/9-46d)	GB7 (TE1p/TE2a/TE2p)	GB18 (IP1)
BL5 (i6-8)	GB8 (PHT/TE1p)	ST8 (6r/IFJp)
BL6 (6a)	GB9 (PH/PHT)	TW22 (TE2a),
BL8 (IP0)	GB14 (a10p/p10p)	GV19 (7PL)
GB4 (6r)	GB15 (8C, Area 46)	

Structurally Connected Acupoints:

BL4 (Area 46/9-46d)
GB7 (TE2a)
GB15 (8C)



Area 8AV

Location:

At the posterior part of the MFG. An anterior-to-posterior band that is medial to area 8C.

Functions:

-Interpretation of complex visual information and attention within the context of spatial working memory.⁸²

Areas 8 and rostral 6, as part of the posterior dorsolateral frontal areas, are also involved in the maintenance of spatial information.⁸¹

Functional Connectivity:

Dorsolateral frontal lobe: 9a, 9p, 9m, 8BL, 8AD, and 8C, i6-8, s6-8

Medial frontal lobe: 8BM, SFL, 10d, d32

Inferior frontal lobe: 44, 45, A47r, 47l, 47s

Premotor region: area 55b

Temporal lobe: TGd, TE1a, TE1m, TE1p, TE2a, STSva, STSvp

Inferior parietal lobe: PFm, IP1, PGi, PGs

Medial parietal lobe: 7m, 31pd, 31pv, 31a, 23d, d23ab, v23ab

White Matter Connections:

Structurally connected to the arcuate/SLF and the contralateral hemisphere. Connections to the contralateral hemisphere travel through the body of the corpus callosum to connect to SFL.

Connections with the arcuate/SLF project posteriorly and wrap around the sylvian fissure to the parietal lobule to end at 6a, 7PC, MIP, PFm, and 2.

Local short association bundles: 8C, 8Ad, i6-8, and area 46

Traditional Acupoint Correlates:

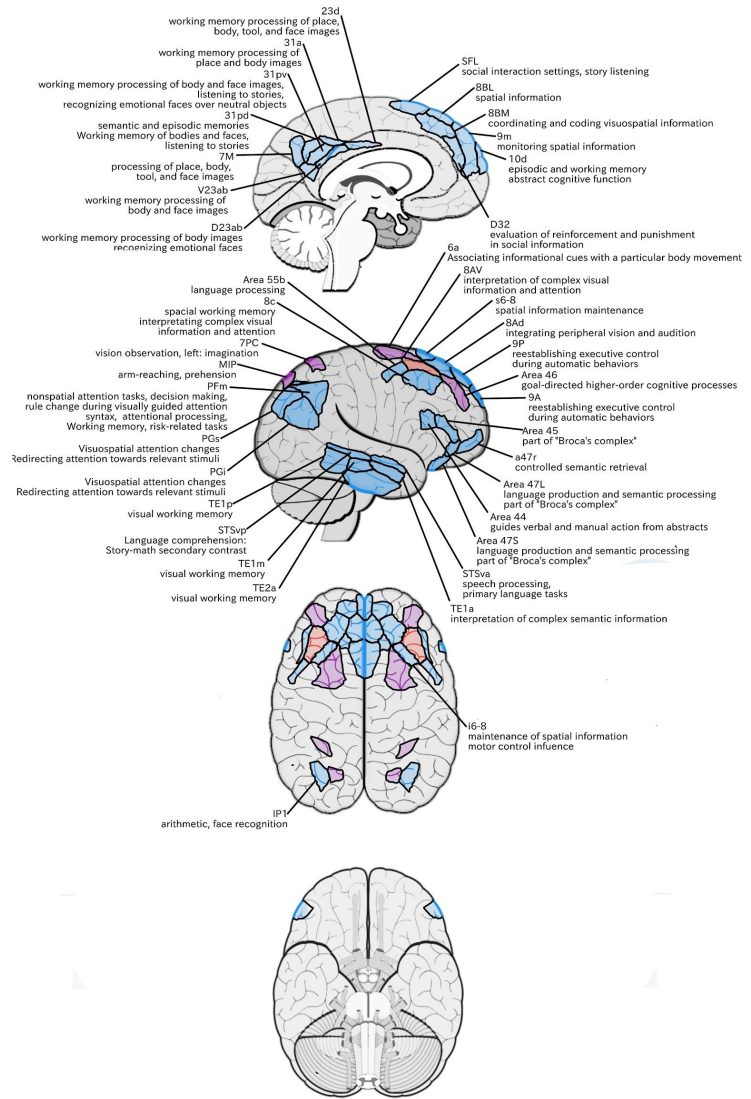
Local Acupoint: BL4, BL5, GB15

Functionally Connected Acupoints:

BL3 (8Ad/8BL)	GB7 (TE1m, TE1p, TE2a)	GV21 (SFL)
BL4 (8Ad)	GB8 (TE1p)	GV22 (8BL)
BL5 (8Ad/i6-8)	GB15 (8C)	GV23 (9m)
BL8 (IP1)	GB18 (IP1)	
GB6 (STSdp/STSva/STSvp/TE1a)	TW22 (TE2a)	

Structurally Connected Acupoints:

BL3 (8Ad)	BL6 (6a)	GB18 (PFm)
BL4 (Area 46, 8Ad)	BL7 (7PC)	GV21 (SFL)
BL5 (8Ad/i6-8)	GB15 (8C)	



Area 8C

Location:

The posterior portion of the MFG. It is an anterior-to-posterior band lateral to area 8AV.

Functions:

-Interpretation of complex visual information and attention within the context of spatial working memory.⁸²

Areas 8 and rostral 6, as part of the posterior dorsolateral frontal areas, are also involved in the maintenance of spatial information.⁸¹

Functional Connectivity:

Dorsolateral frontal lobe: s6-8, i6-8, a9-46v, p9-46v, a10p, 8BL, 8AD, 8AV

Medial frontal lobe: 8BM, d32

Inferior frontal lobe: IFSp, IFJp, a47r, p47r, 44

Insula: AVI

Temporal lobe: TE1m, TE1p, TE2a, STSva, STSvp

Inferior parietal lobe: IP1, IP2, LIPd, PFm, PGI, PGI

Medial parietal lobe: 7pm, 31pv, 31a, POS2, 23d, d23ab

White Matter Connections:

Structurally connected to the arcuate/SLF and the contralateral hemisphere.

Contralateral connections travel through the corpus callosum to end at 8C.

Connections with the arcuate/SLF project posteriorly and wrap around the sylvian fissure to the posterior temporal lobe to end at PH and PHT.

Traditional Acupoint Correlates:

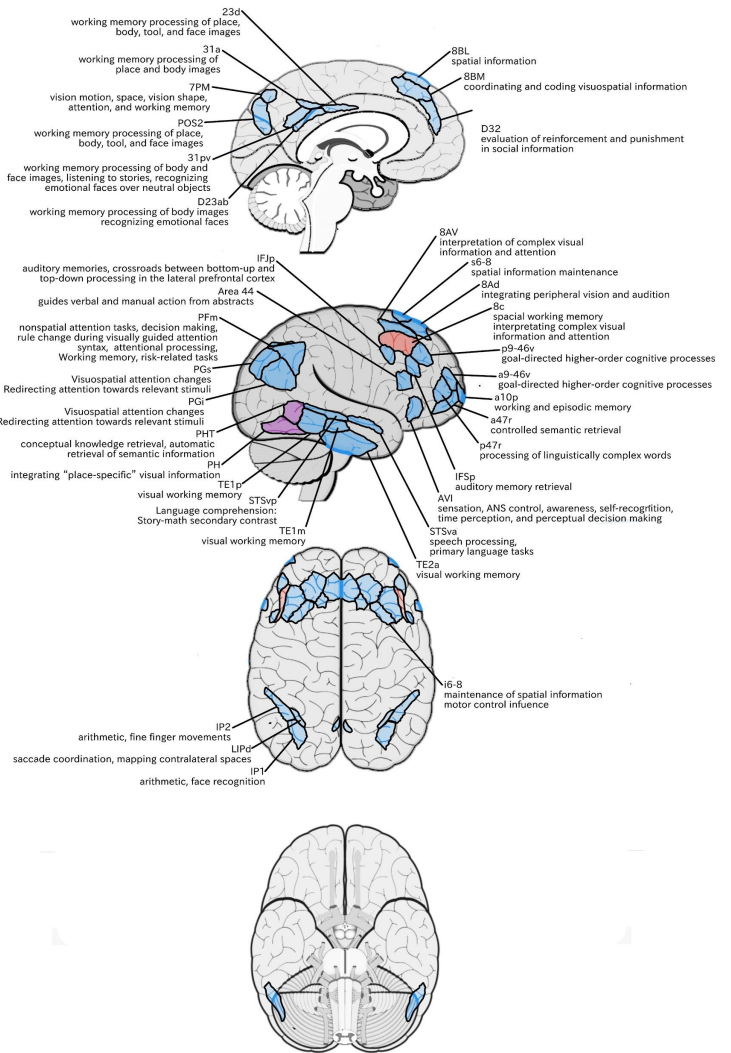
Local Acupoint: GB15

Functionally Connected Acupoints:

BL3 (8AD)	GB7 (TE1m, TE1p, TE2a)	GB18 (IP1)
BL4 (8AD/8AV)	GB8 (TE1p)	TW22 (TE2a)
BL5 (8AD/8AV/i6-8)	GB13 (p9-46v)	GV19 (7PM),
BL8 (IP1)	GB14 (a10p)	GV22 (8BL)
GB6 (STSva/STSvp/TE1a),	GB15 (8AV/p9-46v)	

Structurally Connected Acupoints:

GB8 (PHT)
 GB9 (PH/PHT)
 GB15 (8C)



Area s6-8 (superior 6-8)

Location:

At the posterior most SFG, on its lateral bank near where the SFS joins with the precentral sulcus. Represents a transitional area of cortex between Brodmann areas 6 and 8.

Functions:

Areas 8 and rostral 6 are involved in maintenance of spatial information.⁸⁶ Brodmann area 6 has also been subdivided into areas including the premotor and supplementary motor areas that influence motor control. The premotor area is further divided into ventral and dorsal premotor portions (PMv and PMd, respectively).⁸⁷

PMv contributes to object manipulation with the hands, specifically with precision grip. Additionally, PMv contains mirror neurons.⁸⁷

PMd is involved in selecting motor responses based on arbitrary and spatial cues. PMd also communicates with the prefrontal cortex.

Functional Connectivity:

Dorsolateral prefrontal lobe: i6-8, 8C, 8AD, 8AV
 Medial frontal lobe: 8BM, d32
 Temporal lobe: TE1m, TE1p
 Inferior parietal lobe: PFm, PGs
 Medial parietal lobe: 7pm, 31a, d23ab

White Matter Connections:

Structurally connected to the FAT.
 Connections from the FAT project to the IFG to terminate at 44, FOP4, and 6r.
 Local short association bundles: 8Av.

Traditional Acupoint Correlates:

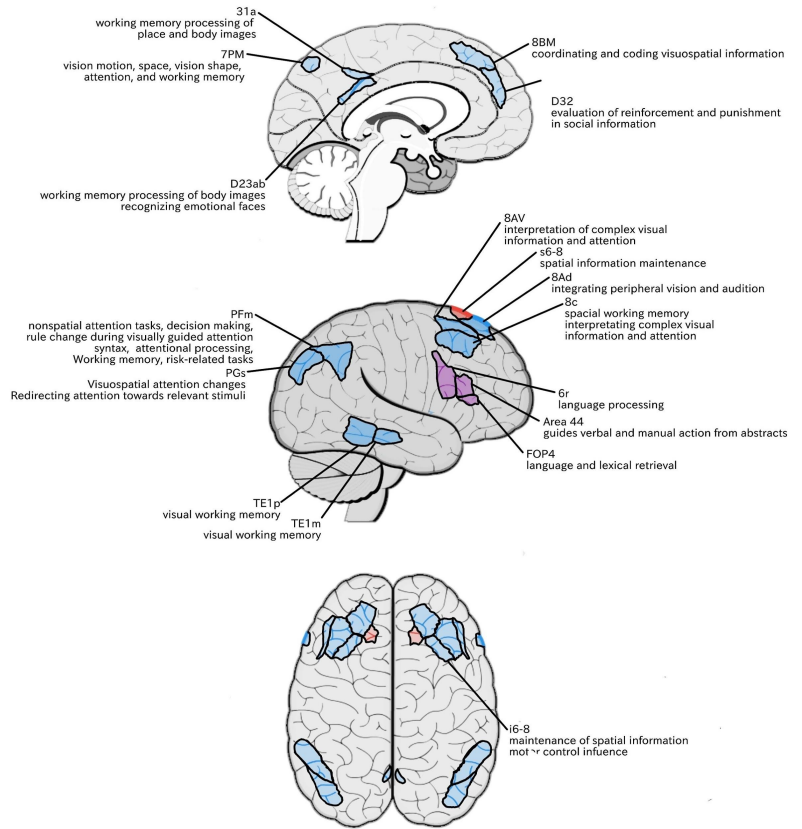
Local Acupoint: N/A (medial to BL5)

Functionally Connected Acupoints:

BL3 (8AD)	GB4 (6r),	GB18 (PFm/PGs),
BL4 (8AD/8Av)	GB7 (TE1m/TE1p)	GV19 (7PM)
BL5 (8AD/8Av/i6-8)	GB15 (8AV/8C)	

Structurally Connected Acupoints:

BL4 (8Av)
 BL5 (8Av)
 GB4 (6r)
 ST8 (6r)



Area i6-8 (inferior 6-8)

Location:

At the posterior medial MFG near where the SFS joins with the precentral sulcus.

Functions:

Areas 8 and rostral 6 are involved in maintenance of spatial information.⁸⁶ Brodmann area 6 has also been subdivided into areas including the premotor and supplementary motor areas that influence motor control. The premotor area is further divided into ventral and dorsal premotor portions (PMv and PMd, respectively).⁸⁷

PMv contributes to object manipulation with the hands, specifically with precision grip. Additionally, PMv contains mirror neurons.⁸⁷

PMd is involved in selecting motor responses based on arbitrary and spatial cues. PMd also communicates with the prefrontal cortex.

Functional Connectivity:

Dorsolateral frontal lobe: s6-8, a9-46v, p9-46v, p10p, 8C, 8AD, 8AV

Medial frontal lobe: 8BM and d32

Inferior frontal lobe: IFSp, IFJp, a47r, p47r, 44

Premotor region: 6a

Temporal lobe: TE1m, TE1p, TE2a, PHA2, PreS

Inferior parietal lobe: IP0, IP1, IP2, LIPd, PFm, and PGs

Medial frontal lobe: 7pm, 7m, 31a, POS2, POS1, d23ab

White Matter Connections:

Structurally connected to surrounding parcellations. White matter tracts from this parcellation are variable.

Local short association bundles: 8Av, 8Ad, 9-46d, 6a, and FEF.

Traditional Acupoint Correlates:

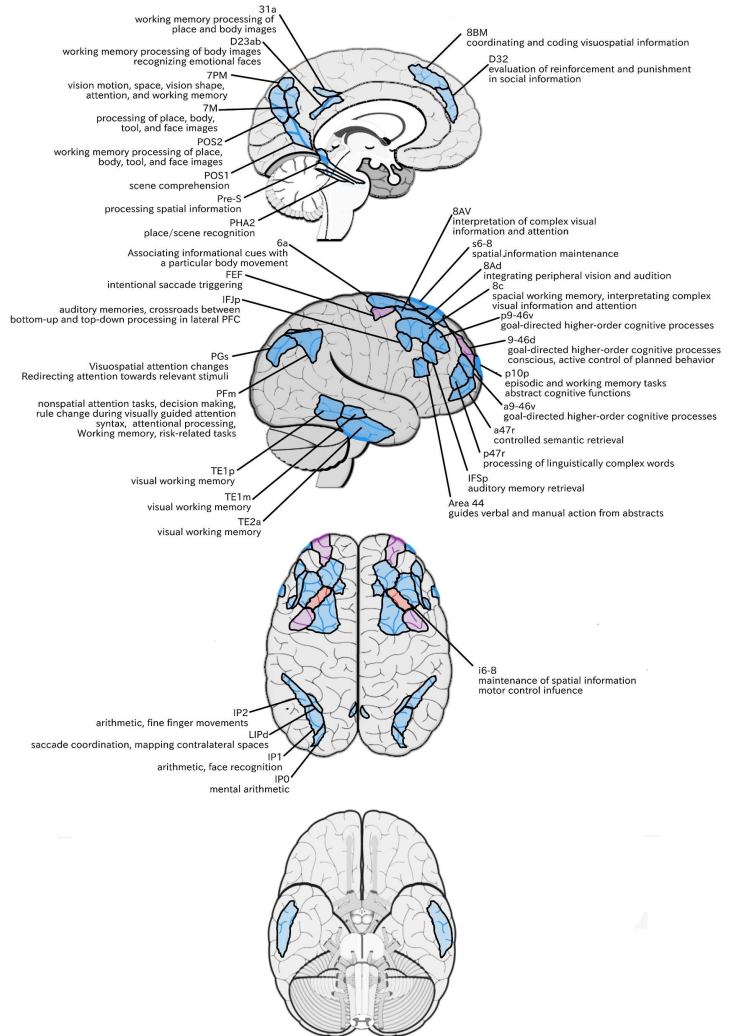
Local Acupoint: BL5

Functionally Connected Acupoints:

BL3 (8Ad)	GB7 (TE1m/TE1p/ TE2a)	GB18 (IP1)
BL4 (8Ad/8Av)	GB8 (TE1p)	ST8 (IFJp)
BL5 (8Ad/8Av)	GB13 (p9-46v)	TW22 (TE2a)
BL6 (6a)	GB14 (p10p)	GV19 (7PM)
BL8 (IP0/IP1)	GB15 (8AV/8C/p9-46v)	

Structurally Connected Acupoints:

BL3 (8Ad)
BL4 (8Ad/8Av/9-46d)
BL5 (8Ad/8Av)
BL6 (6a)
GB16 (FEF)



IFS Regions

Area IFSa

Location:

Located at the anterior portion of the IFS, superior to the pars orbitalis portion of the IFG.

Functions:

Areas in the midventrolateral prefrontal cortex interact with posterior areas of the brain to retrieve specific auditory memories.⁸⁸

The IFS also plays a specific role in creating procedural representations in working memory from verbal instructions.⁸⁹

Functional Connectivity:

Dorsolateral frontal lobe: a47r, p47r, IFSp, IFJa, IFJp, a9-46v, p9-46v, 46

Medial frontal lobe: 8BM, 33prime

Premotor areas: 6ma, 6a, 6r, PEF, FEF

Insula opercular area: FOP4, FOP5, PFop, MI, Pol2

Orbitofrontal region: area 11L

Temporal lobe: PH, PHT, TE1p, TE2p, PeEc, PHA3

Inferior parietal lobe: 7PL, IP0, IP1, IP2, PF, PGP, PFT, AIP, MIP, LIPd

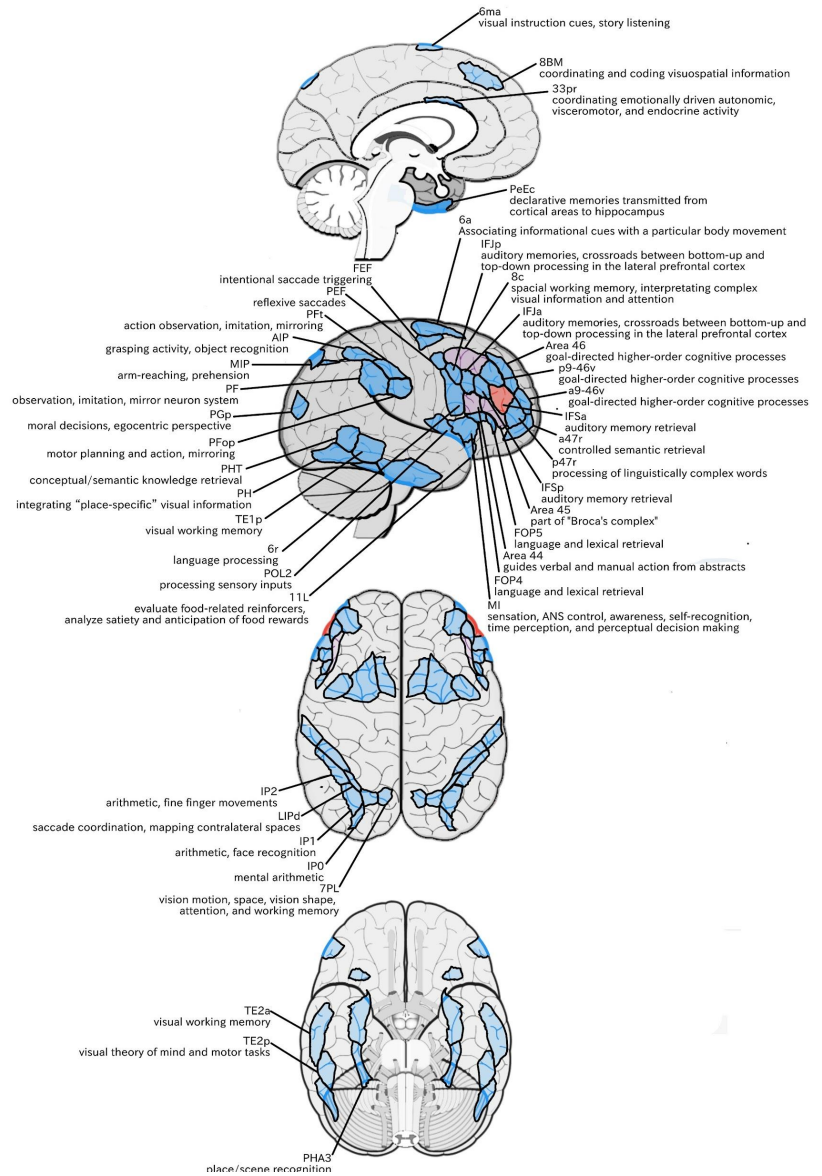
Medial parietal lobe: areas 7am, 23c

White Matter Connections:

Structurally connected with the arcuate/SLF and surrounding parcellations.

Connections with the arcuate/SLF project posteriorly and wrap around the Sylvian fissure to the inferior temporal gyrus to end at TE2a, there are also connections from the arcuate/SLF that end at 4.

Local short association bundles: p47r, 46, p9-46v, 45, IFSa, 8C, 44, IFSp, and a9-46v.



Traditional Acupoint Correlates:

Local Acupoint: N/A (inferior to GB13)

Functionally Connected Acupoints:

BL4 (Area 46)

BL6 (6a)

BL8 (IP0/IP1)

GB4 (6r)

GB5 (POL2)

GB7 (TE1p/ TE2a)

GB8 (TE1p/PHT)

GB9 (PH/PHT)

GB13 (p9-46v)

GB15 (Area 46/p9-46v)

GB16 (FEF)

GB18 (IP1)

ST8 (6r/IFJp/PEF)

TW20 (TE2p)

TW22 (TE2a)

Structurally Connected Acupoints:

GB15 (8C)

TW22 (TE2a)

Area IFSp

Location:

Located at the anterior portion of the IFS, roughly superior to the pars triangularis portion of the IFG.

Functions:

Areas in the midventrolateral prefrontal cortex interact with posterior areas of the brain to retrieve specific auditory memories.⁸⁸

The IFS also plays a specific role in creating procedural representations in working memory from verbal instructions.⁸⁹

Functional Connectivity:

Dorsolateral frontal lobe: a47r, p47r, IFSa, IFJa, IFJp, p9-46v, 47l, 44, 45, i6-8, 8C

Medial frontal lobe: 8BM

Premotor areas: 55b

Orbitofrontal region: 47m

Temporal lobe: PH, TE1p, STSdp, STSvp

Inferior parietal lobe: IP0, IP1, TPOJ1, LIPd

White Matter Connections:

Structurally connected with the arcuate/SLF and surrounding parcellations.

Connections with the arcuate/SLF project posteriorly and wrap around the Sylvian fissure to the middle and inferior temporal gyrus to end at TE1a, TE1m, and TE2a.

Local short association bundles: area 46, IFJa, IFSa, IFSp, TE2a, TE1m, TE1a, 9-46d, p9-46v, 8C, 8Av

Traditional Acupoint Correlates:

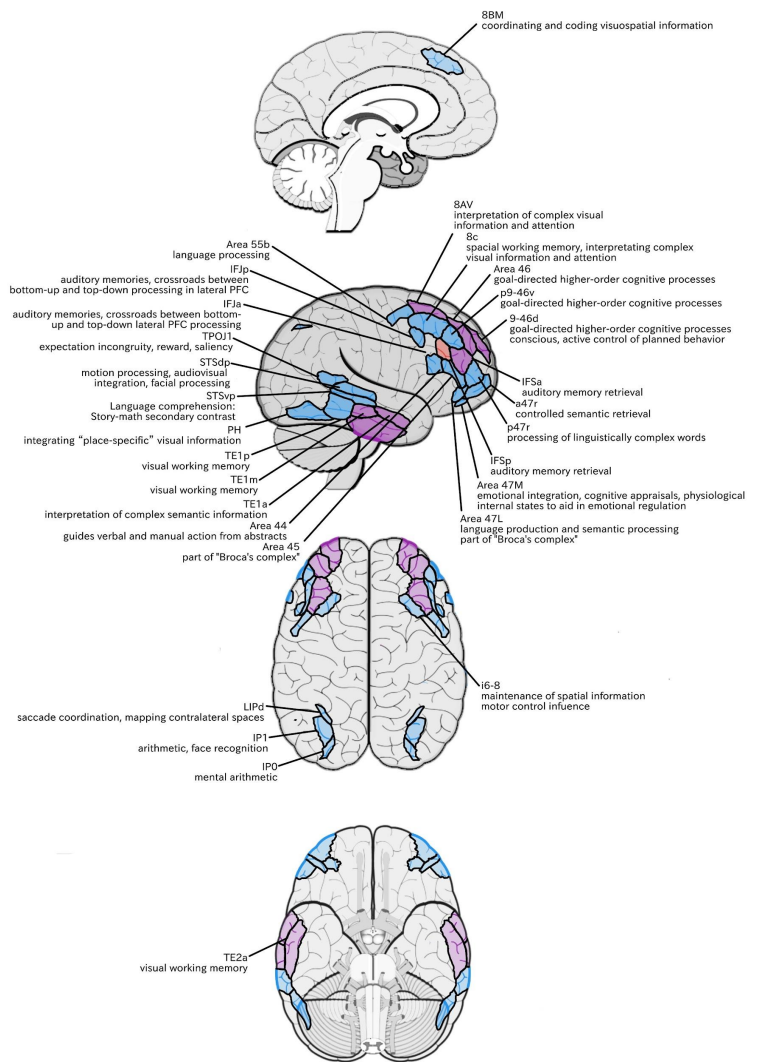
Local Acupoint: N/A (inferior and posterior to GB13)

Functionally Connected Acupoints:

BL5 (i6-8)	GB7 (TE1p)
BL8 (IP0/IP1)	GB8 (TE1p)
GB6 (STSdp, STSvp)	GB9 (PH)

Structurally Connected Acupoints:

BL4 (8Av/9-46d/Area 46)
 BL5 (8Av)
 GB7 (TE1m/TE2a)
 GB13 (p9-46v)
 GB15 (p9-46v/8C)
 TW22 (TE2a)



Area IFJa

Location:

In the posterior portion of the IFS, roughly superior to the pars opercularis portion of the IFG.

Functions:

-An important crossroads between bottom-up and top-down processing in the lateral prefrontal cortex.⁹⁰

Areas in the midventrolateral PFC interact with posterior areas of the brain to retrieve specific auditory memories.⁸⁸

Functional Connectivity:

Dorsolateral prefrontal lobe: 44, IFSa, IFSp, IFJp, p9-46v

Medial frontal lobe: area SCEF

Premotor areas: areas FEF, 55b PEF, 6r

Insular opercular: area FOP5 and PSL

Temporal lobe: areas PH, PHT, TE2p

Inferior parietal lobe: areas MIP, TPOJ1, LIPd

White Matter Connections:

Structurally connected with the arcuate/SLF and surrounding parcellations.

Connections with the arcuate/SLF project posteriorly and wrap around the Sylvian fissure to the middle and inferior temporal gyrus to end at TE1a, TE1m, and TE2a. These fibers are likely portions of the FAT that has the majority of its inferior terminations at 44.

Local short association bundles: 8c, IFJa, IFSp, 44, 8Av.

Traditional Acupoint Correlates:

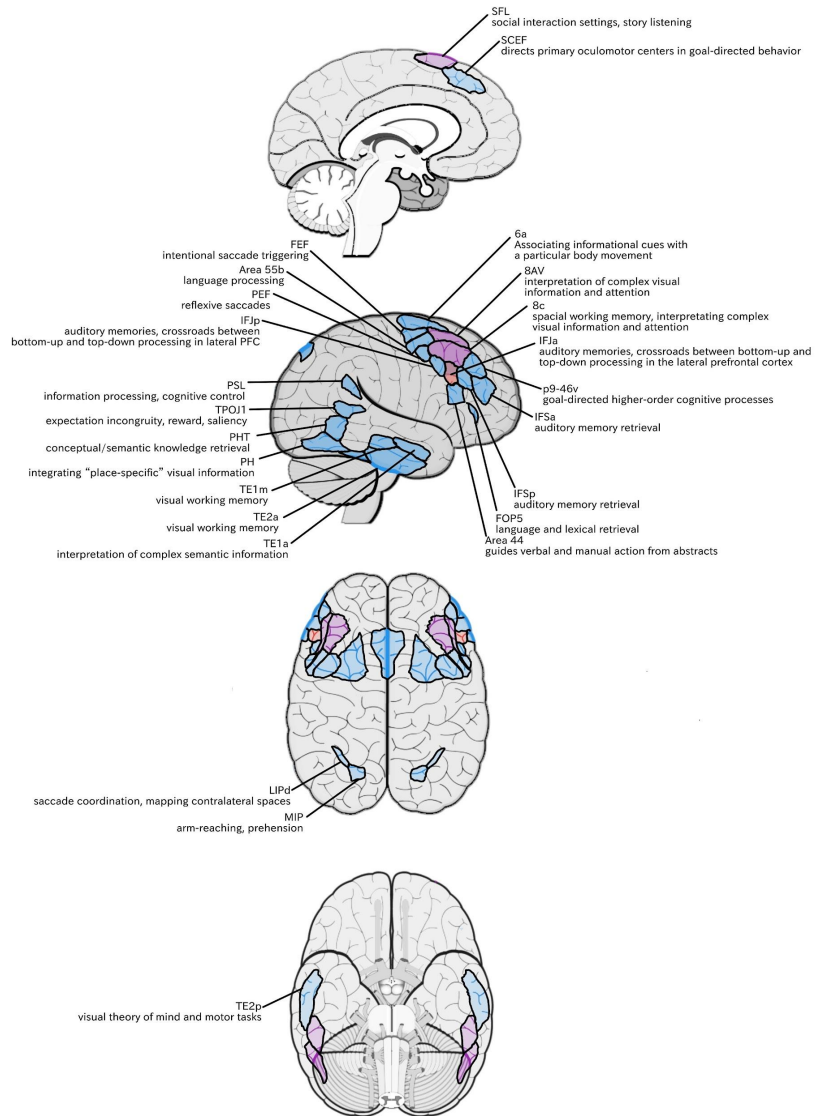
Local Acupoint: N/A (central between GB 4, GB13, and ST8)

Functionally Connected Acupoints:

BL6 (6a)	GB13 (p9-46v)	TW20 (TE2p)
GB7 (TE1m/TE2a)	GB15 (8C/p9-46v)	TW22 (TE2a)
GB8 (PHT)	GB16 (55b/FEF)	GV21 (SFL)
GB9 (PH/PHT)	ST8 (IFJp)	

Structurally Connected Acupoints:

BL4 (8Av)
BL5 (8Av)
GB7 (TE1m/TE2a)
GB15 (8C)



Area IFJp

Location:

At the posterior most part of the IFS, roughly superior to pars opercularis of the IFG.

Functions:

-An important crossroads between bottom-up and top-down processing in the lateral prefrontal cortex.⁹⁰

Areas in the midventrolateral PFC interact with posterior areas of the brain to retrieve specific auditory memories.⁸⁸

Functional Connectivity:

Dorsolateral frontal lobe: p47r, IFSa, IFJa, IFJp, p9-46v, i6-8, 8C

Medial frontal lobe: 8BM, 33prime

Premotor areas: 6r, 6a, PEF

Temporal lobe: PH, PHT, TE1p, TE2p

Inferior parietal lobe: 7PL, PFt, PF, IP0, IP1, IP2, AIP, MIP, LIPd

Medial parietal lobe: 7PM

White Matter Connections:

Area IFJp is structurally connected with the arcuate/SLF and surrounding parcellations. Connections with the arcuate/SLF project posteriorly and wrap around the Sylvian fissure to the posterior temporal gyrus to end at PHT and FST.

There are also connections from the arcuate/SLF to PFm.

Local short association bundles: 8C, IFJa, IFJp, IFSp, 44, 6r, PEF.

Traditional Acupoint Correlates:

Local Acupoint: ST8

Functionally Connected Acupoints:

BL5 (i6-8)

BL6 (6a)

BL8 (IP0/IP1)

GB4 (6r)

GB7 (TE1p)

GB8 (TE1p/PHT)

GB9 (PH/PHT)

GB13 (p9-46v)

GB18 (IP1)

ST8 (6r)

TW20 (TE2p)

Structurally Connected Acupoints:

GB4 (6r)

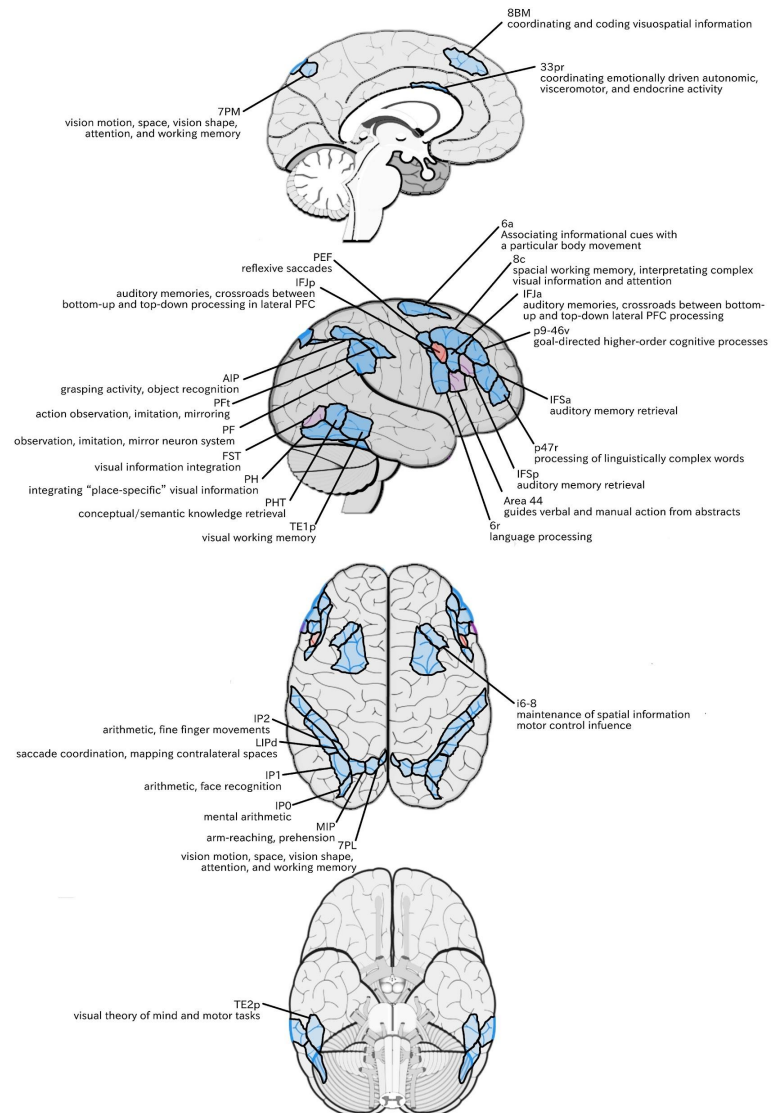
GB8 (PHT)

GB9 (PHT)

GB15 (8C)

GB18 (PFm)

ST8 (IFJp/PEF)



IFG Regions

Area 44

Location:

At the posterior most part of the IFG. The anterior bank of pars opercularis of the IFG.

Functions:

-Translates abstract and intentional information in the prefrontal cortex to more detailed representations to guide verbal and manual actions.⁹¹

In addition to association with Broca's area, sometimes represented as part of "Broca's complex," including Brodmann areas 45, 46, 47, and the mesial supplementary motor area of 6, which contribute to a frontal-subcortical circuit.⁹²

The right pars opercularis has been implicated in cognitive inhibition in working memory.⁹⁴

Functional Connectivity:

Dorsolateral frontal lobe: SFL, IFSp, IFJa, 45, 47s, 47L, 9a, 9m, 8AV, 8BL, 8C

Medial frontal lobe: 8BM

Premotor areas: 55b

Insula-opercular region: FOP5, AVI, PSL

Temporal lobe: TGd, STSdp, STSvp

Inferior parietal lobe: areas PFm, PGI

White Matter Connections:

Structurally connected to the arcuate/SLF and the FAT. Connections with the arcuate/SLF wrap around the Sylvian fissure to end at TE1a and TE1m. There are also projections from the arcuate/SLF before it terminates to A5 and STSdp. The majority of the inferior connections of the FAT end at 44, the tract connects superiorly SFL, 6ma and s6-8.

Local short association bundles: area 45 and 8C.

White matter tracts from 44 in the right hemisphere have less consistent connections with the arcuate/SLF.

Traditional Acupoint Correlates:

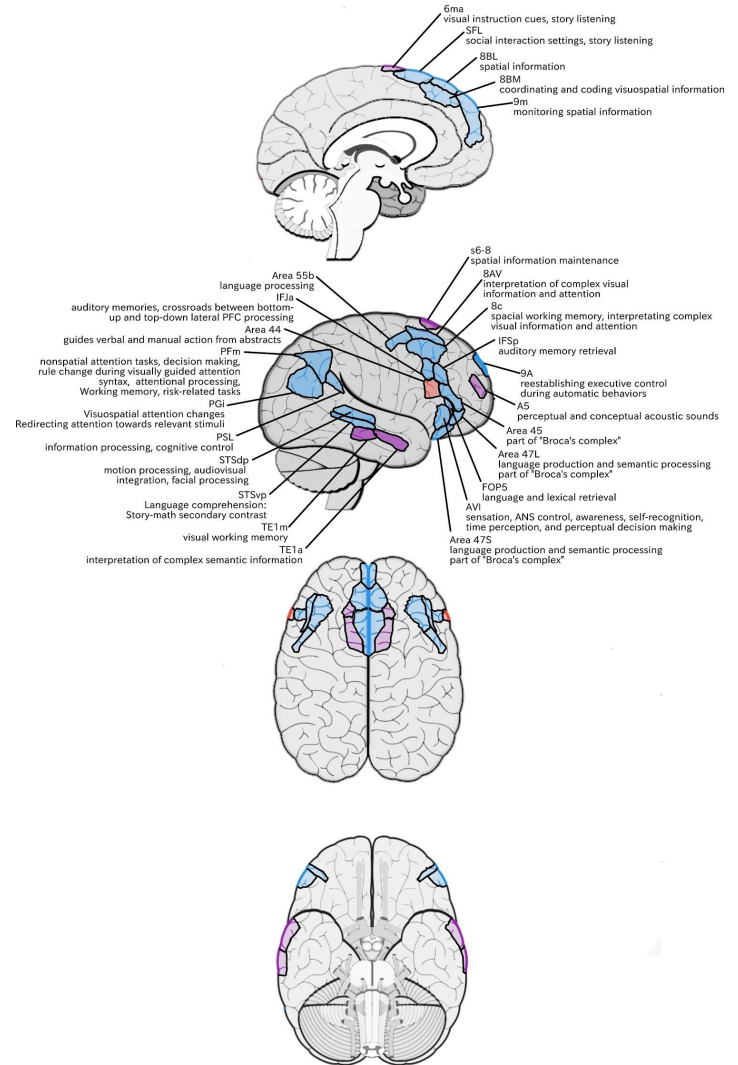
Local Acupoint: N/A (anterior to GB4)

Functionally Connected Acupoints:

BL4 (8AV)	GB7 (TE1m)	GV21 (SFL)
BL5 (8AV)	GB15 (8AV/8C)	GV22 (8BL)
GB6 (STSvp/TE1a)	GB16 (55b)	GV23 (9m)

Structurally Connected Acupoints:

GB6 (TE1a/STSdp)	GB7 (TE1m)	GV21 (SFL)
------------------	------------	------------



Area 45

Location:

The lateral surface of pars triangularis of the IFG.

Functions:

In addition to its known association with Broca's area, is sometimes represented as part of "Broca's complex," including Brodmann areas 45, 46, 47, and the mesial supplementary motor area of 6, which contribute to a frontal-subcortical circuit.⁹²

Functional Connectivity?

Dorsolateral frontal lobe: SFL, IFSp, 44, a47r, 47s, 47L, 9a, 9p, 9m, 8AV, 8BL

Medial frontal lobe: 8BM

Premotor areas: 55b

Insula-opercular region: FOP5, and PSL

Temporal lobe: TGd, TGv, TE1a, STSva, STSdp, STSvp

Inferior parietal lobe: PGI

Medial parietal lobe: 31pd

White Matter Connections:

Structurally connected to the arcuate/SLF and IFOF. However, not consistently across individuals. Connections with the arcuate/SLF wrap around the Sylvian fissure to the middle temporal gyrus to end at TE1p. There are also projections from the arcuate/SLF before it terminates to A4 and PBelt. IFOF connections travel from 45 through the extreme/external capsule and continue posteriorly through the temporal lobe to end at V1, V2, V3, and V4.

Local short association bundles: area 44 and FOP4

Traditional Acupoint Correlates:

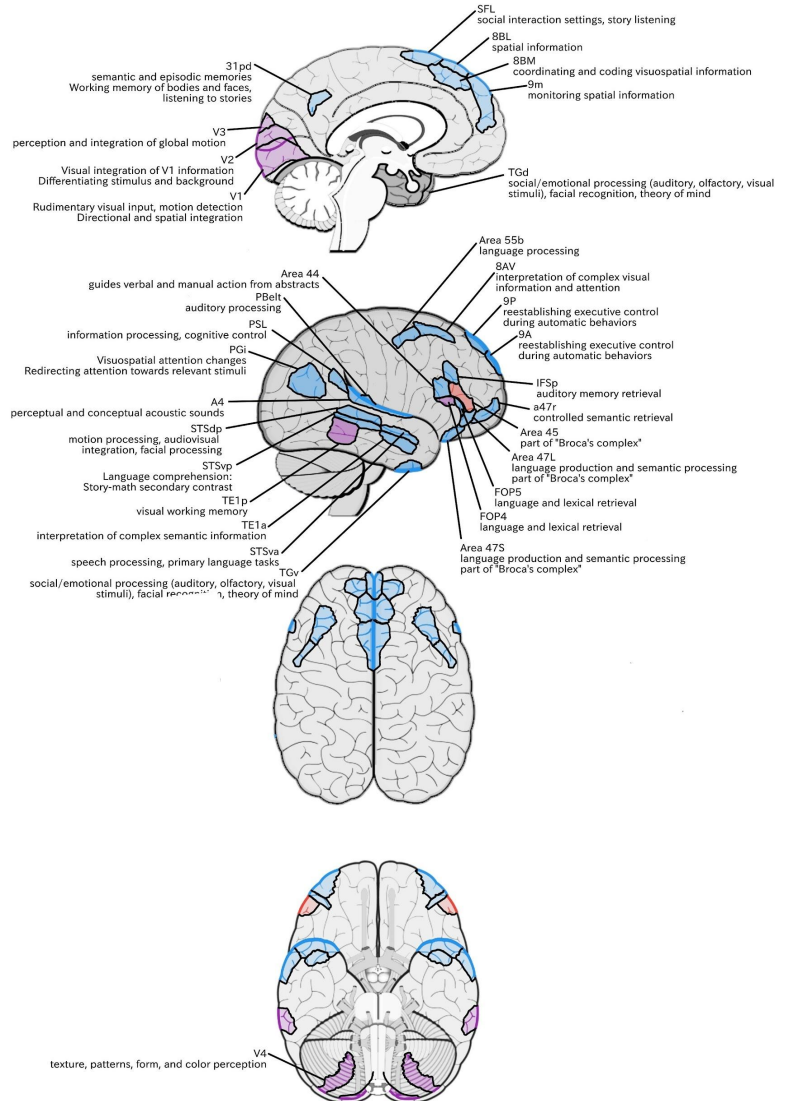
Local Acupoint: N/A (½ the distance between GB4 and GB13)

Functionally Connected Acupoint:

BL3 (9P)	GB6 (STSdp/STSva/STSvp)	GV22 (8BL)
BL4 (8AV)	GB15 (8AV)	GV23 (9m)
BL5 (8AV)	GB16 (55b)	
GB5 (A4)	GV21 (SFL)	

Structurally Connected Acupoints:

- GB5 (A4)
- GB7 (TE1p)
- GB8 (TE1p)
- GV18 (V1/V2)



Area 47L

Location:

Part of the pars orbitalis of the IFG, lying on the inferolateral border near the posterior boundary.

Functions:

-Several language processes, including language production and semantic processing.⁹⁴

Area 47, in addition to its known association with Broca's area, is sometimes represented as part of "Broca's complex," including Brodmann areas 45, 46, 47, and the mesial supplementary motor area of 6, which contribute to a frontal-subcortical circuit.⁹²

Functional Connectivity:

Dorsolateral frontal lobe: SFL, IFSp, 45, 44, a47r, 47s, 9a, 9p, 9m, 8AV, 8BL
 Medial frontal lobe: 8BM, 10v
 Premotor areas: 55b
 Temporal lobe: TGd, TE1a, STSda, STSdp, STSva
 Inferior parietal lobe: PGI
 Medial parietal lobe: 31pd, 31pv

White Matter Connections:

Structurally connected to the IFOF and uncinate fasciculus.
 IFOF connections travel from 47L through the extreme/external capsule and continue posteriorly through the temporal lobe to end at V1, V2, V3, and V4.
 Uncinate fibers course inferiorly through the limen insulae to the temporal pole to end at TGd and STGa.
 Local short association bundles: area 45 and FOP5.
 White matter tracts in the right hemisphere do not have consistent connections with the uncinate fasciculus.

Traditional Acupoint Correlates:

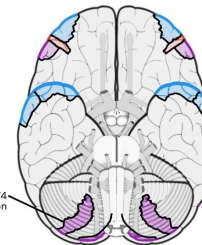
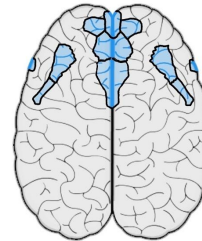
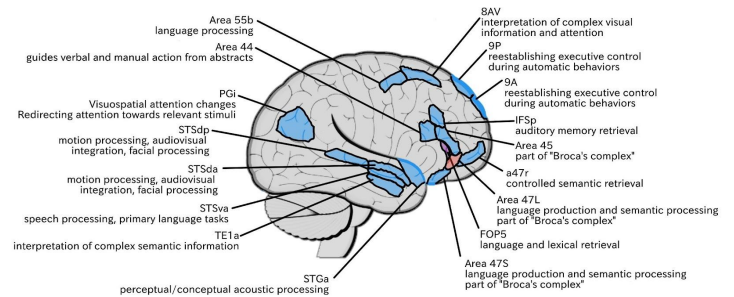
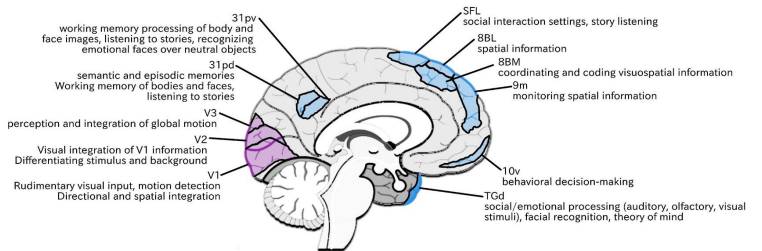
Local Acupoint: N/A (approximately extra point Tai Yang at the temple)

Functionally Connected Acupoints:

BL3 (9P)	GB6 (STSds/STSdp/STSva)	GV21 (SFL)
BL4 (8AV)	GB15 (8AV)	GV22 (8BL)
BL5 (8AV)	GB16 (55b)	GV23 (9m)

Structurally Connected Acupoints:

GV18 (V1/V2)



V4 texture, patterns, form, and color perception

Area 47s

Location:

Located on the posterior bank of the pars orbitalis of the IFG as it folds over onto the orbitofrontal surface.

Functions:

-Several language processes, including language production and semantic processing.⁹⁴

Area 47, in addition to its known association with Broca's area, is sometimes represented as part of "Broca's complex," including Brodmann areas 45, 46, 47, and the mesial supplementary motor area of 6, which contribute to a frontal-subcortical circuit.⁹²

Functional Connectivity?:

Dorsolateral frontal lobe: SFL, 45, 44, 47L, 9a, 9p, 9m, 8AV, 8BL
 Medial frontal lobe: d32
 Insula: area AAIC
 Temporal lobe: TGd, TE1a, STSdp, STSvp, STSva
 Inferior parietal lobe: PGI
 Medial parietal lobe: 7M, 31pd, 31pv

White Matter Connections:

Structurally connected to the IFOF and uncinate fasciculus.

IFOF connections travel through the extreme/external capsule and continue posteriorly to end at V1, V2, and V3. Uncinate fibers course inferiorly through the limen insulae to the temporal pole to end at TGd. There are also anterior uncinate projections that end at frontal polar parcellations 10v and 10pp.

Traditional Acupoint Correlates:

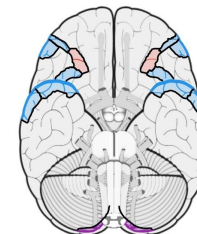
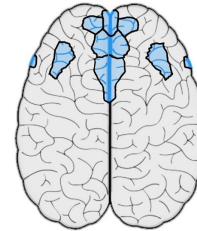
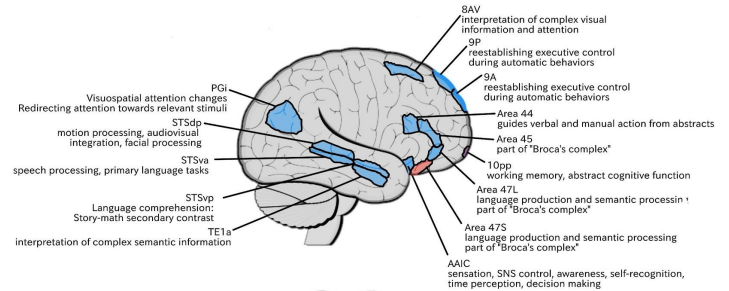
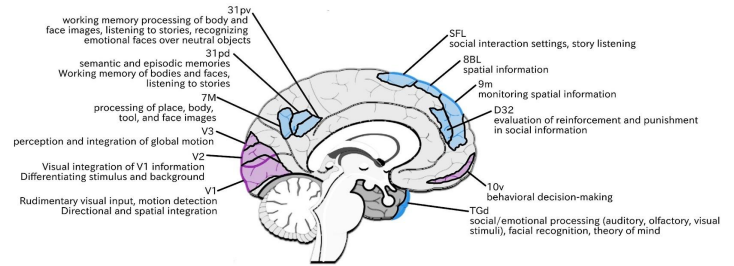
Local Acupoint: N/A (posterior to TW23)

Functionally Connected Acupoints:

BL3 (9P)	GB6 (STSdp/STSva/STSvp)	GV22 (8BL)
BL4 (8AV)	GB15 (8AV)	GV23 (9m)
BL5 (8AV)	GV21 (SFL)	

Structurally Connected Acupoints:

GV18 (V1/V2)
 Yintang (10v)



Discussion

By assessing the cortical regions that may be directly and indirectly affected by non-invasive neuromodulatory techniques of localized stimulus such as acupuncture or other methods such as Transcranial Magnetic Stimulation (TMS) and transcranial Direct Current Stimulation electrical current (tDCS), from the perspective of brain network dynamics based on connectomic modeling we can begin to form a functional model from which to consider treatment approaches where cortical stimulation may be of great interest such as traumatic brain injury, stroke, or a variety of other neuropathological disorders or imbalances. Practitioners may consider selecting a number of supportive nodes to stimulate based on functionally or structurally connected regions to the primary focal region. As lesion network mapping becomes better developed and understood clinical pictures and assessment may be more readily considered based on interconnected and interacting brain networks and neural connections rather than isolated regional lesion pathologies.

In the case of traumatic brain injury, even in cases of direct focal lesioning, rarely is a straightforward clinical picture of regional pathology seen. Much of this may be due to the impact on the neural connections to other interconnected cortical regions, which may affect functioning throughout that neural connection or network. As neuroscience comes to understand the complexities of neural networking more deeply and are better able to assess their functioning in both healthy and pathological states, taking a clinical approach that utilizes this knowledge may offer a better means of maximizing clinical outcomes and expanding research potential in gauging brain network neuromodulation techniques relative to other approaches.

In this series traditional acupuncture points and their corresponding cortical regions are utilized in order to build upon an existing system both for ease and as a reference for those versed in acupuncture theory to perhaps expand their knowledge or consideration of scalp acupoints and their clinical indications. By doing this however, while all cortical parcellations will be described within this series, only those cortical regions that lie at a traditional acupuncture point are listed as functionally or structurally connected points and leave functionally or structurally connected regions without a direct traditional acupoint to reference not listed. This is a limitation of this article series at this time but beyond the scope of this series to directly address and may be a direction of future exploration.

Scalp acupuncture utilizing existing points and scalp microsystems have been demonstrated for a wide variety of neuropathologies and by further understanding the functional network dynamics of the brain we may be able to better utilize that knowledge to further optimize therapeutic benefit in a range of neuropathologies.

Conflict of Interest Statement

The authors declare that the research was conducted in the absence of any commercial or financial relationships that could be construed as a potential conflict of interest.

Table 1 Traditional Acupuncture Points Associations With The Lateral Frontal Lobe

Acupoint	Cortical Parcellation Correlation
BL3	8Ad, 8BL, 9P
BL4	8Ad, 8AV, 9-46d, Area 46
BL5	8Ad, 8Av, i6-8
BL6	6a
BL7	7AL, 7PC
BL8	IP0, IP1
GB4	6r, Area 43
GB5	A4, POL2
GB6	STSds, STSdp, STSva, STSvp, TE1a, TE1p
GB7	TE1m, TE1p, TE2a, TE2p
GB8	PHT, TE1p
GB9	PH, PHT
GB12	6r
GB13	p9-46v
GB14	a10p, a47r, p10p
GB15	8AD, 8AV, 8C, p9-46v, Area 46
GB16	55b, FEF
GB18	AIP, PFM, PGMs, IP1
ST8	6r, IFJp, PEF
TW20	TE2p
TW22	TE2a
GV18	V1, V2
GV19	7PM, V6a
GV21	SFL
GV22	8BL
GV23	9m, 10d
GV24	10d
Yintang	10v

References

1. Zhe Liu, Ling Guan, Yan Wang, Cheng-Long Xie, Xian-Ming Lin, Guo-Qing Zheng, "History and Mechanism for Treatment of Intracerebral Hemorrhage with Scalp Acupuncture", *Evidence-Based Complementary and Alternative Medicine*, vol. 2012, Article ID 895032, 9 pages, 2012. <https://doi.org/10.1155/2012/895032>
2. Deadman, P., Al-Khafaji, M., & Baker, K. In *A manual of acupuncture*. 2016. Journal of Chinese Medicine Publications.
3. Hao, J. J., & Hao, L. L. *Chinese scalp acupuncture*. 2011. Blue Poppy Press.
4. www.scalpacupuncture.org. Website. Retrieved May 31, 2022.
5. Feely, R. A., & Yamamoto, T. (2011). *Yamamoto New Scalp acupuncture: Principles and practice*. Thieme.
6. Nam., J. Chan. S. (2020). In *Head acupuncture of dr. Shun Fa Jiao*. essay, LULU COM.
7. Jiao, S. F. (1982) *Scalp Acupuncture*, Shanxi People' s Publishing House, Taiyuan, China, 1st edition.
8. Liu, Z., Guan, L., Wang, Y., Xie, C-L, Lin, X-M, Zheng, G-Q. History and mechanism for treatment of intracerebral hemorrhage with scalp acupuncture", *Evidence-Based Complementary and Alternative Medicine*. 2012; 2012, Article ID 895032, 9 pages. <https://doi.org/10.1155/2012/895032>
9. Shuya Wang, Kun Liu, Yuan Wang, Shuyou Wang, Xun He, Xiang Cui, Xinyan Gao, and Bing Zhu. *Medical Acupuncture*. Oct 2017; 29(5).322-326. <http://doi.org/10.1089/acu.2017.1231>
10. Ratmansky, M., Levy, A., Messinger, A., Birg, A., Front, L., Treger, L.. The Effects of Acupuncture on Cerebral Blood Flow in Post-Stroke Patients: A Randomized Controlled Trial. *The Journal of Alternative and Complementary Medicine*. Jan 2016; 22(1).33-37. <http://doi.org/10.1089/acm.2015.0066>
11. Liu H, Chen L, Zhang G, et al. Scalp Acupuncture Enhances the Functional Connectivity of Visual and Cognitive-Motor Function Network of Patients with Acute Ischemic Stroke. *Evid Based Complement Alternat Med*. 2020;2020:8836794. Published 2020 Dec 2. doi:10.1155/2020/8836794
12. Hommer, D. Chinese Scalp Acupuncture Relieves Pain and Restores Function in Complex Regional Pain Syndrome, *Military Medicine*, Oct 2012; 177(10), 1231–1234, <https://doi.org/10.7205/MILMED-D-12-00193>
13. Liu, H., Jiang, Y., Wang, N., Chen, L., Gao, J., Zhang, J., et al..Functional Connection Changes among Cerebral Regions and between Hemispheres in the Acute Ischemic Stroke Patients Treated by Scalp Acupuncture: A Rs-fMRI Study. 2020; 10.21203/rs.3.rs-104143/v1.
14. Liu H, Jiang Y, Wang N, Yan H, Chen L, Gao J, Zhang J, Qu S, Liu S, Liu G, Huang Y, Chen J. Scalp acupuncture enhances local brain regions functional activities and functional connections between cerebral hemispheres in acute ischemic stroke patients. *Anat Rec (Hoboken)*. 2021 Nov;304(11):2538-2551. doi: 10.1002/ar.24746.
15. Sizhu, J., Zhang, G., Li, K., Lang, Y., Tan, Z., Zhang, Y., Zou, Y., Wu, Y., Cui, F. A resting-state functional magnetic resonance imaging study on the efficacy of brain function rehabilitation in post-stroke hemiplegia using scalp acupuncture. *Journal of Medical Imaging and Health Informatics*. 2015; 5. 1752-1758. 10.1166/jmihi.2015.1640.
16. Cao J, Huang Y, Meshberg N, Hodges SA, Kong J. Neuroimaging-Based Scalp Acupuncture Locations for Dementia. *J Clin Med*. 2020;9(8):2477. Published 2020 Aug 1. doi:10.3390/jcm9082477
17. Cao J, Chai-Zhang TC, Huang Y, Eshel MN, Kong J. Potential scalp stimulation targets for mental disorders: evidence from neuroimaging studies. *J Transl Med*. 2021;19(1):343. Published 2021 Aug 10. doi:10.1186/s12967-021-02993-1
18. Cao, J., Hunag, Y., Hodges, S., Meshberg, N., Kong, J. Identify potential neuroimaging-based scalp acupuncture and neuromodulation targets for anxiety. *Brain Science Advances*. 2021; 7(2), 97-111. <https://doi.org/10.26599/BSA.2021.9050011>
19. Bai, L., Zhang, D., Cui, T-T, Li, J-F, Gao, Y-Y, et al..Mechanisms underlying the antidepressant effect of acupuncture via the CaMK signaling pathway. *Front. Behav. Neurosci*. 04 December 2020 <https://doi.org/10.3389/fnbeh.2020.563698>
20. Jittiwat, J. Laser acupuncture at GV20 improves brain damage and oxidative stress in animal model of focal ischemic stroke. *Journal of Acupuncture and Meridian Studies*. Oct 2017; 10(5), 324-330. <https://doi.org/10.1016/j.jams.2017.08.003>
21. Litscher G, Zhang X, Sheng Z, Jing XH, Wang L. Multimodal laser stimulation and traditional needle acupuncture in post-stroke patients-a pilot cross-over study with results from near infrared spectroscopy. *Medicines (Basel)*. 2019;6(4):115. Published 2019 Dec 16. doi:10.3390/medicines6040115

22. To WT, De Ridder D, Hart J Jr, Vanneste S. Changing Brain Networks Through Non-invasive Neuromodulation. *Front Hum Neurosci.* 2018;12:128. Published 2018 Apr 13. doi:10.3389/fnhum.2018.00128
23. Medeiros LF, de Souza IC, Vidor LP, et al. Neurobiological effects of transcranial direct current stimulation: a review. *Front Psychiatry.* 2012;3:110. Published 2012 Dec 28. doi:10.3389/fpsy.2012.00110
24. Shapira-Lichter I., Oren N., Jacob Y., Gruberger M., Hendler T. Portraying the unique contribution of the default mode network to internally driven mnemonic processes. *Proc. Natl. Acad. Sci. U S A* 2013; 110, 4950–4955. 10.1073/pnas.1209888110
25. Radman T., Ramos R. L., Brumberg J. C. Bikson M. Role of cortical cell type and morphology in subthreshold and suprathreshold uniform electric field stimulation *in vitro*. *Brain Stimul.* 2009; 2, 215–228, 228.e1–228.e3. 10.1016/j.brs.2009.03.007
26. Filmer H. L., Dux P. E., Mattingley J. B. Applications of transcranial direct current stimulation for understanding brain function. *Trends Neurosci.* 2014; 37, 742–753. 10.1016/j.tins.2014.08.003
27. Horvath J. C., Carter O., Forte J. D. Transcranial direct current stimulation: five important issues we aren't discussing (but probably should be). *Front. Syst. Neurosci.* 2014; 8:2. 10.3389/fnsys.2014.00002
28. Thirugnanasambandam N., Grundey J., Adam K., Drees A., Skwirba A. C., Lang N., et al.. Nicotinic impact on focal and non-focal neuroplasticity induced by non-invasive brain stimulation in non-smoking humans. *Neuropsychopharmacology* 2011; 36, 879–886. 10.1038/npp.2010.227
29. Sale M. V., Ridding M. C., Nordstrom M. A. Factors influencing the magnitude and reproducibility of corticomotor excitability changes induced by paired associative stimulation. *Exp. Brain Res.* 2007; 181, 615–626. 10.1007/s00221-007-0960-x
30. Abraham W. C. Metaplasticity: tuning synapses and networks for plasticity. *Nat. Rev. Neurosci.* 2008; 9:387. 10.1038/nrn2356
31. Hulme S. R., Jones O. D., Abraham W. C. Emerging roles of metaplasticity in behavior and disease. *Trends Neurosci.* 2013; 36, 353–362. 10.1016/j.tins.2013.03.007
32. Alon, G., Roys, S.R., Gullapalli, R.P., Greenspan, J.D. Non-invasive electrical stimulation of the brain (ESB) modifies the resting-state network connectivity of the primary motor cortex: A proof of concept fMRI study. *Brain Research.* 27 July 20011; 1403, 37-44. <https://doi.org/10.1016/j.brainres.2011.06.013>
33. Fox, M., Buckner, R., Liu, H. Resting-state networks link invasive and noninvasive brain stimulation across diverse psychiatric and neurological diseases. *PNAS.* Sept 29 2014. <https://doi.org/10.1073/pnas.140500311>
34. To WT, De Ridder D, Hart J Jr, Vanneste S. Changing Brain Networks Through Non-invasive Neuromodulation. *Front Hum Neurosci.* 2018;12:128. Published 2018 Apr 13. doi:10.3389/fnhum.2018.00128
35. Luft CD, Pereda E, Banissy MJ, Bhattacharya J. Best of both worlds: promise of combining brain stimulation and brain connectome. *Front Syst Neurosci.* 2014;8:132. Published 2014 Jul 30. doi:10.3389/fnsys.2014.00132
36. Sara Ryding Reviewed by Dr. Surat P. *What is Connectomics?* News. 2019, April 11. Retrieved May 31, 2022, from <https://www.news-medical.net/life-sciences/What-is-Connectomics.aspx>
37. <http://www.humanconnectomeproject.org/>. Human Connectome Project. Website. Retrieved May 31, 2022
38. <https://www.o8t.com/connectomics#sectionone>. Omniscient Neurotechnology. Website. Retrieved May 31, 2022
39. Glasser MF, Coalson TS, Robinson EC, Hacker CD, Harwell J, Yacoub E, Ugurbil K, Andersson J, Beckmann CF, Jenkinson M, Smith SM, Van Essen DC. A multi-modal parcellation of human cerebral cortex. *Nature.* 2016 Aug 11;536(7615):171-178. doi: 10.1038/nature18933.
40. Baker CM, Burks JD, Briggs RG, et al. A Connectomic Atlas of the Human Cerebrum-Chapter 1: Introduction, Methods, and Significance. *Oper Neurosurg (Hagerstown).* 2018;15(suppl_1):S1-S9. doi:10.1093/ons/opy253
41. Bullmore, E., Sporns, O. Complex brain networks: graph theoretical analysis of structural and functional systems. *Nature reviews. Neuroscience.* 2009; 10, 186-98. 10.1038/nrn2575.
42. Atasoy, S., Donnelly, I. & Pearson, J. Human brain networks function in connectome-specific harmonic waves. *Nat Commun.* 2016; 7, 10340. <https://doi.org/10.1038/ncomms10340>
43. Freeman, L.C. A set of measures of centrality based on betweenness. *Sociometry* 1977; 40, 35–41.

44. Fox, M. Mapping symptoms to brain networks with the human connectome. *New England Journal of Medicine*. 2018; 379. 2237-2245. 10.1056/NEJMra1706158.
45. Carrera E, Tononi G. Diaschisis: past, present, future. *Brain* 2014; 137: 2408-22
46. Fornito A, Zalesky A, Breakspear M. The connectomics of brain disorders. *Nat Rev Neurosci* 2015; 16: 159-72
47. Warren DE, Power JD, Bruss J, et al. Network measures predict neuropsychological outcome after brain injury. *Proc Natl Acad Sci USA* 2014; 111: 14247-52.
48. Baker CM, Burks JD, Briggs RG, et al. A Connectomic Atlas of the Human Cerebrum-Chapter 1: Introduction, Methods, and Significance. *Oper Neurosurg (Hagerstown)*. 2018;15(suppl_1):S1-S9. doi:10.1093/ons/opy253
49. Koechlin, E., Summerfield, C.. An information theoretical approach to prefrontal executive function. *Trends in Cognitive Sciences*. 2007;11. 229-35. 10.1016/j.tics.2007.04.005
50. Chan R. C., Shum D., Touloupoulou T., Chen E. Y. (2008). Assessment of executive functions: review of instruments and identification of critical issues. *Arch. Clin. Neuropsychol.* 23, 201–216. 10.1016/j.acn.2007.08.010
51. Wood RL, Worthington A. Neurobehavioral Abnormalities Associated with Executive Dysfunction after Traumatic Brain Injury. *Front Behav Neurosci*. 2017;11:195. Published 2017 Oct 26. doi:10.3389/fnbeh.2017.00195.
52. Friedman, N.P., Robbins, T.W. The role of prefrontal cortex in cognitive control and executive function. *Neuropsychopharmacol.* 2022; 47, 72–89. <https://doi.org/10.1038/s41386-021-01132-0>
53. Chen, Jen-Kai & Johnston, Karen & Petrides, Michalakis & Ptitto, Alain. Recovery from mild head injury in sports: evidence from serial functional magnetic resonance imaging studies in male athletes. *Clinical Journal of Sport Medicine : official journal of the Canadian Academy of Sport Medicine*. 2008;18. 241-7. 10.1097/JSM.0b013e318170b59d.
54. Shenton ME, Hamoda HM, Schneiderman JS, et al. A review of magnetic resonance imaging and diffusion tensor imaging findings in mild traumatic brain injury. *Brain Imaging Behav*. 2012;6(2):137-192. doi:10.1007/s11682-012-9156-5
55. Carrick, F. TBI: Advancements in Diagnosis & Treatment. Lecture. Jan 11-13, 2019
56. Luft CD, Pereda E, Banissy MJ, Bhattacharya J. Best of both worlds: promise of combining brain stimulation and brain connectome. *Front Syst Neurosci*. 2014;8:132. Published 2014 Jul 30. doi:10.3389/fnsys.2014.00132
57. Liu W, Leng YS, Zou XH, Cheng ZQ, Yang W, Li BJ. Affective Processing in Non-invasive Brain Stimulation Over Prefrontal Cortex. *Front Hum Neurosci*. 2017;11:439. Published 2017 Sep 4. doi:10.3389/fnhum.2017.00439
58. Peña-Gómez C, Sala-Lonch R, Junqué C, et al. Modulation of large-scale brain networks by transcranial direct current stimulation evidenced by resting-state functional MRI. *Brain Stimul*. 2012;5(3):252-263. doi:10.1016/j.brs.2011.08.006
59. Fox MD, Snyder AZ, Vincent JL, Corbetta M, Van Essen DC, Raichle ME. The human brain is intrinsically organized into dynamic, anticorrelated functional networks. *Proc Natl Acad Sci U S A*. 2005;102(27):9673-9678. doi:10.1073/pnas.0504136102
60. Antonenko, Daria & Abbarin, Maral & Escher, Malvin & Flöel, Agnes & Schubert, Torsten. Modulation of dual-task control with right prefrontal transcranial direct current stimulation (tDCS). *Experimental Brain Research*. 2018; 236. 227-241. 10.1007/s00221-017-5121-2.
61. Kang, E.K., Kim, D.Y., Paik N.J. Transcranial direct current stimulation of the left prefrontal cortex improves attention in patients with traumatic brain injury: a pilot study. *Journal of Rehabilitation Medicine*, 01 Apr 2012, 44(4):346-350. DOI: 10.2340/16501977-0947
62. Lee, S.A., Kim, M.-K. Effect of Low Frequency Repetitive Transcranial Magnetic Stimulation on Depression and Cognition of Patients with Traumatic Brain Injury: A Randomized Controlled Trial. *Med Sci Monit*. 2018; 24: 8789–8794. Published online 2018 Dec 4. doi: 10.12659/MSM.911385
63. Boggio PS, Fregni F, Bermanpohl F, Mansur CG, Rosa M, Rumi DO, Barbosa ER, Odebrecht Rosa M, Pascual-Leone A, Rigonatti SP, Marcolin MA, Araujo Silva MT. Effect of repetitive TMS and fluoxetine on cognitive function in patients with Parkinson's disease and concurrent depression. *Mov Disord*. 2005 Sep;20(9):1178-84. doi: 10.1002/mds.20508.

64. Liu, W., Leng, Y.S., Zou, X.H., Cheng, Z.Q., Yang, W., Li, B.J. Affective Processing in Non-invasive Brain Stimulation Over Prefrontal Cortex. *Front Hum Neurosci.* 2017; 11: 439. Published online 2017 Sep 4. doi: 10.3389/fnhum.2017.00439
65. Fregni, F., Boggio, P.S., Nitsche, M. et al. Anodal transcranial direct current stimulation of prefrontal cortex enhances working memory. *Exp Brain Res.* 2005; 166, 23–30. <https://doi.org/10.1007/s00221-005-2334-6>
66. Nelson, J., McKinley, R. A., Golob, E., Warm, J., Parasuraman, Enhancing vigilance in operators with prefrontal cortex transcranial direct current stimulation (tDCS). *NeuroImage.* Jan 2014; 85(3), 909-917. <https://doi.org/10.1016/j.neuroimage.2012.11.061>
67. Boggio PS, Rocha M, Oliveira MO, et al. Noninvasive brain stimulation with high-frequency and low-intensity repetitive transcranial magnetic stimulation treatment for posttraumatic stress disorder. *J Clin Psychiatry.* 2010;71(8):992-999. doi:10.4088/JCP.08m04638blu
68. Watts, B., Landon, B., Groft, A., Yinong, Y.-X. A sham controlled study of repetitive transcranial magnetic stimulation for posttraumatic stress disorder. *Brain Stimulation.* Jan 2012; 5(1), 38-43. <https://doi.org/10.1016/j.brs.2011.02.002>
69. Ferrucci R., Mameli F., Guidi I., Mrakic-Sposta S., Vergari M., Marceglia S., et al.. Transcranial direct current stimulation improves recognition memory in Alzheimer disease. *Neurology.* 2008; 71, 493–498. 10.1212/01.wnl.0000317060.43722.a3
70. Brunelin J, Mondino M, Gassab L, Haesebaert F, Gaha L, Suaud-Chagny MF, Saoud M, Mechri A, Poulet E. Examining transcranial direct-current stimulation (tDCS) as a treatment for hallucinations in schizophrenia. *Am J Psychiatry.* 2012 Jul;169(7):719-24. doi: 10.1176/appi.ajp.2012.11071091.
71. Prikryl R., Ustohal L., Prikrylova Kucerova H., Kasperek T., Venclikova S., Vrzalova M., et al.. A detailed analysis of the effect of repetitive transcranial magnetic stimulation on negative symptoms of schizophrenia: a double-blind trial. *Schizophr. Res.* 2013; 149, 167–173. 10.1016/j.schres.2013.06.015
72. Mishra B. R., Nizamie S. H., Das B., Praharaj S. K. Efficacy of repetitive transcranial magnetic stimulation in alcohol dependence: a sham-controlled study. *Addiction.* 2010; 105, 49–55. 10.1111/j.1360-0443.2009.02777.x)
73. Van den Eynde F., Claudino A. M., Mogg A., Horrell L., Stahl D., Ribeiro W., et al.. Repetitive transcranial magnetic stimulation reduces cue-induced food craving in bulimic disorders. *Biol. Psychiatry.* 2010; 67, 793–795. 10.1016/j.biopsych.2009.11.023
74. Chahine G, Diekhof EK, Tinnermann A, Gruber O. On the role of the anterior prefrontal cortex in cognitive 'branching': an fMRI study. *Neuropsychologia.* 2015;77:421-429.
75. Bludau S, Eickhoff SB, Mohlberg H et al.. Cytoarchitecture, probability maps and functions of the human frontal pole. *Neuroimage.* 2014;93(pt 2):260-275.
76. Fonteneau E, Bozic M, Marslen-Wilson WD. Brain network connectivity during language comprehension: interacting linguistic and perceptual subsystems. *Cereb Cortex.* 2015;25(10):3962-3976.
77. Zhuang J, Tyler LK, Randall B, Stamatakis EA, Marslen-Wilson WD. Optimally efficient neural systems for processing spoken language. *Cereb Cortex.* 2014;24(4):908-918.
78. Roux F, Wibrat M, Mohr HM, Singer W, Uhlhaas PJ. Gamma-band activity in human prefrontal cortex codes for the number of relevant items maintained in working memory. *J Neurosci.* 2012;32(36):12411-12420.
79. Kubler A, Dixon V, Garavan H. Automaticity and reestablishment of executive control-an fMRI study. *J Cogn Neurosci.* 2006;18(8):1331-1342.
80. Lanzilotto M, Perciavalle V, Lucchetti C. Evidence for a functional subdivision of premotor ear-eye field (area 8B). *Front Behav Neurosci.* 2014;8:454.
81. Petrides M, Pandya DN. Dorsolateral prefrontal cortex: comparative cytoarchitectonic analysis in the human and the macaque brain and corticocortical connection patterns. *Eur J Neurosci.* 1999;11(3):1011-1036.
82. Reser DH, Burman KJ, Yu HH et al.. Contrasting patterns of cortical input to architectural subdivisions of the area 8 complex: a retrograde tracing study in marmoset monkeys. *Cereb Cortex.* 2013;23(8):1901-1922.
83. Arnott SR, Binns MA, Grady CL, Alain C. Assessing the auditory dual-pathway model in humans. *Neuroimage.* 2004;22(1):401-408.
84. Courtney SM, Petit L, Haxby JV, Ungerleider LG. The role of prefrontal cortex in working memory: examining the contents of consciousness. *Philos Trans R Soc Lond B Biol Sci.* 1998;353(1377):1819-1828.
85. Nitschke K, Kosterling L, Finkel L, Weiller C, Kaller CP. A Meta-analysis on the neural basis of planning: Activation likelihood estimation of functional brain imaging results in the Tower of London task. *Hum Brain Mapp.* 2017;38(1):396-413.

86. Petrides M. Lateral prefrontal cortex: architectonic and functional organization. *Philos Trans R Soc Lond B Biol Sci.* 2005;360(1456):781-795.
87. Chouinard PA, Paus T. The primary motor and premotor areas of the human cerebral cortex. *Neuroscientist.* 2006;12(2):143-152.
88. Kostopoulos P, Petrides M. Selective memory retrieval of auditory what and auditory where involves the ventrolateral prefrontal cortex. *Proc Natl Acad Sci U S A.* 2016;113(7):1919-1924.
89. Demanet J, Liefoghe B, Hartstra E, Wenke D, De Houwer J, Brass M. There is more into 'doing' than 'knowing': The function of the right inferior frontal sulcus is specific for implementing versus memorizing verbal instructions. *Neuroimage.* 2016;141:350-356.
90. Muhle-Karbe PS, Derrfuss J, Lynn MT et al.. Co-Activation-Based parcellation of the lateral prefrontal cortex delineates the inferior frontal junction area. *Cereb Cortex.* 2016;26(5):2225-2241.
91. van Schie HT, Toni I, Bekkering H. Comparable mechanisms for action and language: neural systems behind intentions, goals, and means. *Cortex.* 2006;42(4):495-498.
92. Ardila A, Bernal B, Rosselli M. How localized are language brain areas? A review of brodmann areas involvement in oral language. *Arch Clin Neuropsychol.* 2016;31(1):112-122.
93. Nissim NR, O'Shea AM, Bryant V, Porges EC, Cohen R, Woods AJ. Frontal structural neural correlates of working memory performance in older adults. *Front Aging Neurosci.* 2016;8:328.
94. Ardila A, Bernal B, Rosselli M. Should Broca's area include Brodmann area 47? *Psicothema.* 2017;29(1):73-77.